

Eye Emergency Manual

An illustrated guide

THIRD EDITION, DECEMBER 2023

Agency for Clinical Innovation

1 Reserve Road, St Leonards NSW 2065
Locked Bag 2030, St Leonards NSW 1590

Phone: +61 2 9464 4666 | Email: aci-info@health.nsw.gov.au | Web: aci.health.nsw.gov.au

Further copies of this publication can be obtained from the Agency for Clinical Innovation website at aci.health.nsw.gov.au

Disclaimer: the content within this publication was accurate at the time of publication.

© State of New South Wales (Agency for Clinical Innovation) 2023. Creative Commons Attribution-No Derivatives 4.0 licence. For current information go to: aci.health.nsw.gov.au. The ACI logo and cover image are excluded from the Creative Commons licence and may only be used with express permission.

Title	Eye Emergency Manual, 3rd Edition		
Published	December 2023		
Next review	2028		
Produced by	ACI Ophthalmology Network		
Preferred citation	<i>NSW Agency for Clinical Innovation. Eye Emergency Manual, 3rd Edition. Sydney: ACI; 2023.</i>		
TRIM ACI/D23/169	SHPN (ACI) 230806	ISBN 978-1-76023-644-1	ACI_8666 [11/23]

Contents

Background	1	Visual requirements for driving	41
Introduction	3	Prevention of visual impairment	42
Anatomy	4	Eye trauma	43
Anatomy terms	5	Blunt ocular trauma	44
Eye assessments	6	Chemical burns	46
History to ascertain	7	Closed globe injury	49
Assessing the severely injured patient	15	Flash burns	51
Paediatric assessment	16	Lid laceration	52
Examinations	18	Non-accidental injury (NAI)	54
Examination essentials	18	Open globe injury (penetrating eye injury)	55
General inspection and assessment of periocular and globe trauma	20	Orbital fracture	57
Visual acuity	23	Retrobulbar haemorrhage (orbital compartment syndrome)	59
Pupil examination	27	Acute visual disturbance	61
Visual field, eye movements and eyelid examination	29	Third (3rd) cranial nerve palsy	62
Eyelid eversion	33	Fourth (4th) cranial nerve palsy	63
Special eye examinations	34	Sixth (6th) cranial nerve palsy	65
Direct ophthalmoscope	34	Central retinal artery occlusion (CRAO)	66
Checking intraocular pressure	35	Central retinal vein occlusion (CRVO)	68
Slit lamp	37	Central serous chorioretinopathy	69
Eye referrals and discharge advice	40	Dry eye/exposure keratopathy	70
Trauma communication checklist	40	Giant cell arteritis (GCA)/anterior ischaemic optic neuropathy (AION)	72
Acute visual disturbance communication checklist	40	Idiopathic intracranial hypertension (IIH): transient visual obscuration	73
Red eye or eyelid communication checklist	40	Intermittent angle closure/ acute angle closure	75
		Lens subluxation	76

Macular haemorrhage in wet age-related macular degeneration	77	Herpes simplex virus keratitis (HSV/HSK)	106
Macular pathology	78	Herpes zoster ophthalmicus (HZO)/shingles	108
Migraine	78	Hyphaema	109
Myasthenia gravis	79	Hypopyon	111
Optic neuritis	80	Marginal keratitis	112
Posterior vitreous detachment (PVD)	81	Neovascular glaucoma	113
Retinal tear or detachment	83	Ophthalmia neonatorum (neonatal conjunctivitis)	114
Thyroid eye disease	84	Preseptal cellulitis (periorbital cellulitis)	116
Transient ischaemic attack (amaurosis fugax) or retinal emboli	85	Pterygium	118
Visual pathway lesion	87	Scleritis	119
Vitreous haemorrhage	87	Subconjunctival haemorrhage	121
Acute red eye or eyelid	89	Trichiasis	122
Acute red eye overview	90	Viral conjunctivitis	123
Acute angle closure crisis	91	Treatments	125
Acute blepharitis	93	Ocular drugs	126
Allergic conjunctivitis	94	How to put in eye drops	130
Iritis (anterior uveitis or an anterior chamber inflammation)	95	References	131
Bacterial or acanthamoebal ulcer	96	Appendix: Evidence base	133
Bacterial conjunctivitis	97	PubMed search terms	133
Chalazion/stye	98	Google search terms	133
Corneal or conjunctival foreign body/corneal abrasion	100	Inclusion and exclusion criteria	133
Ectropion	103	Bibliography	133
Entropion	104	Glossary	135
Episcleritis	105		
Eyelid lesion	106		

Background

The Eye Emergency Manual (EEM) is designed for medical, nursing and allied health staff in emergency departments and critical care, and for rural general practitioners.

The EEM has not undergone a formal process of evidence-based clinical practice guideline development; however, it is the result of consensus opinion determined by relevant experts. The EEM is not a definitive statement on correct procedures; rather, it is a general guide to be followed subject to clinical judgement. The EEM is based on the best information available at the time of writing.

The EEM was first released in 2007 and last updated in 2009. The current review was undertaken by the ACI Ophthalmology Network with oversight by a clinical working group led by Dr Parth Shah.

Method

The EEM was reviewed formally by members of a working group, including clinicians in ophthalmology, optometry, orthoptics, emergency and critical care, and rural general practice across NSW. Data for the EEM were drawn from a literature search, consensus expert opinion of the working group and consultation.

Rapid, targeted literature searches of PubMed were conducted in June and July 2023. Searches were related to: eye diseases OR eye injuries AND emergency treatment AND guidelines OR principles.

Grey literature searches were completed using Google and Google Scholar.

Refer to "Appendix: Evidence base" for search terms and reference list.

Consultation

The following groups were consulted for this revision:

- Members of the working group (as listed under 'Acknowledgements' below)
- ACI Networks
- Survey respondents

The Eye Emergency Manual is endorsed by the Australian College of Emergency Nursing and the Save Sight Institute, University of Sydney.

Acknowledgements

Parth Shah, Ophthalmologist, Prince of Wales Hospital and Sydney Children's Hospital

Claire Cuppitt, General Practitioner

Lin Davis, Nurse Educator, Rural Critical Care, Hunter New England LHD

Michael Golding, Emergency Physician, Prince of Wales Hospital

Paula Katalinic, Optometrist and Professional Services and Advocacy Manager, Optometry NSW/ACT

Yves Kerdraon, Ophthalmologist, Sydney Hospital/ Sydney Eye Hospital and Concord Hospital

Kerrie Martin, Ophthalmology Network and Clinical Genetics Network Manager, Agency for Clinical Innovation

Erin McArthur, Project Officer, Agency for Clinical Innovation

Peter McCluskey, Professor and Chair of Ophthalmology, University of Sydney and Director, Save Sight Institute

Joanna McCulloch, Clinical Nurse Consultant Ophthalmology, Sydney Hospital/Sydney Eye Hospital

Danielle Morgan, Acting Deputy Head of Orthoptic Department, Sydney Hospital/Sydney Eye Hospital

David Murphy, Director of Emergency Medicine, Prince of Wales Hospital

Introduction

The EEM is designed to provide a quick and simple guide to recognising important signs and symptoms, and assisting with the management of common eye emergencies. The EEM will also assist with triaging patients to appropriate care.



Each condition has red flags used to increase the triage weighting or indicate urgent ophthalmic referral with an explanation of relevance.

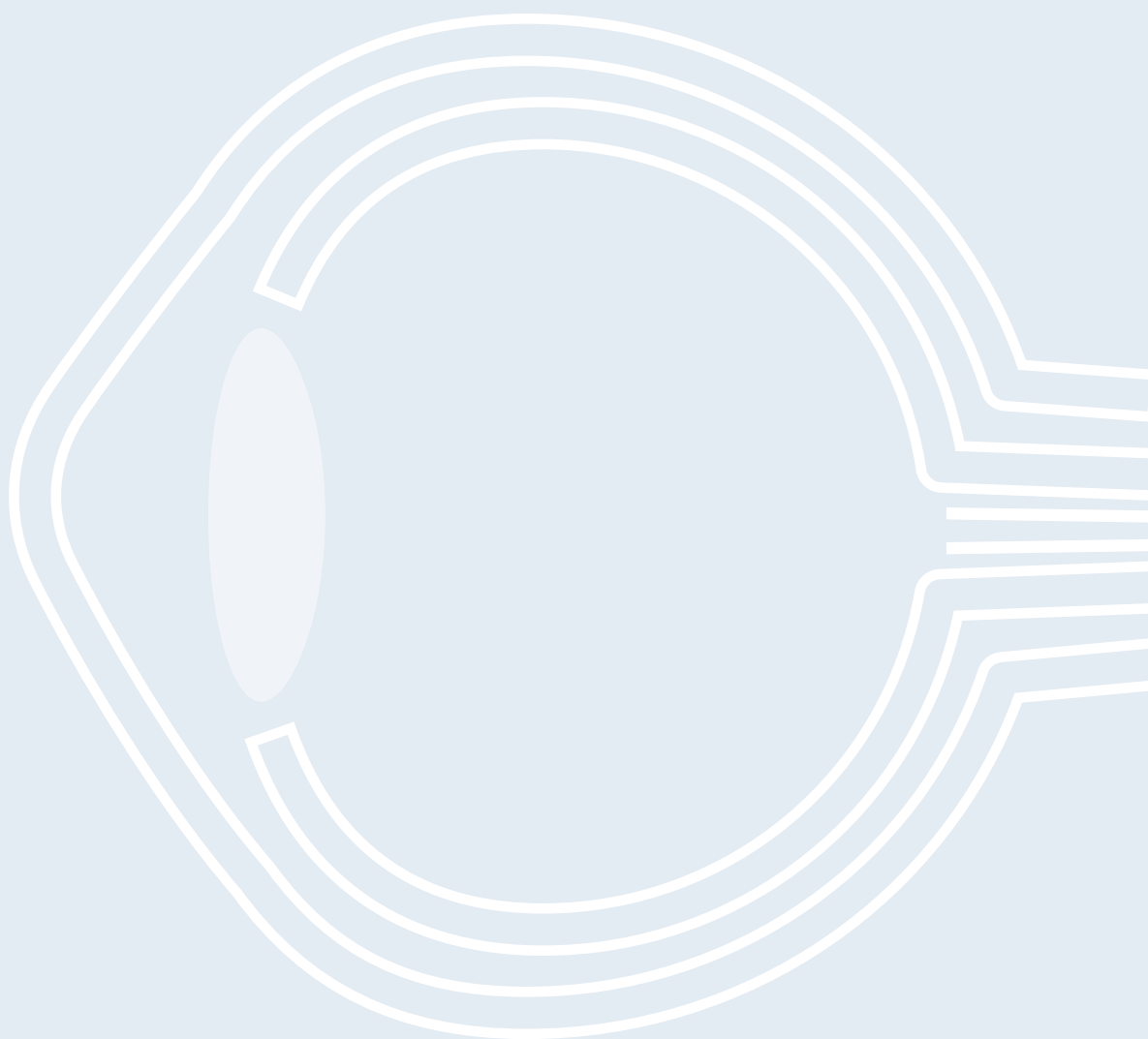
How to use this resource

For ease of use, the EEM has a large amount of graphic content and is divided into basic ophthalmic diagnostic techniques/treatment and management of common eye presentations.

Each condition includes information about:

- immediate action (if any)
- history
- examination
- treatment
- communication checklist(s).

Anatomy



Anatomy

Anatomy terms

Useful terms when describing an eye lesion

- Right vs. left
- Globe vs. eyelids vs. periocular region
- Nasal (medial) vs. temporal (lateral)
- Superior vs. inferior (relative to the pupil)
- Corneal clock hours (as seen by the examiner, e.g. 3 o'clock is the temporal limbus of the left eye)
- Surface area of the cornea, e.g. 30% ulcer

Useful pathological terms

- Ulcer (loss of epithelium from the cornea, conjunctiva or eyelid skin)
- White dot on the cornea or opacification: try to differentiate between infiltrate (abscess/infection), long-standing scar, foreign body or hazy cornea
- Redness on the conjunctiva: try to differentiate between conjunctival injection, subconjunctival haemorrhage and inflamed conjunctival lesion, e.g. pterygium or pingueculum
- Laceration (partial- or full-thickness if involving the cornea, conjunctiva, sclera or eyelid)
- Blunt or sharp eye injury (depending on the object used)
- Penetrating wound (which enters the full thickness of the cornea or sclera)
- Leaking or sealed wound: use Seidel test to determine if a penetrating wound is actively leaking

Eye assessments



Eye assessments

History to ascertain



Basics

- Age
- Allergies



Reason for presentation

- Visual loss
- Eye pain
- Eye redness
- Trauma
- Foreign body
- Chemical injury
- Flashes/floaters
- Diplopia (double vision)



If a chemical injury is suspected, postpone further history-taking or examination and immediately begin irrigation of the eye(s).



Mode of presentation

- Post trauma
- Self-presenting due to symptoms
- Via general practitioner (GP) or optometrist



Past medical history

- Including microvascular risk factors
- Social history
- Medications



Ophthalmic background

- Glasses: distance/reading/bifocals/multifocals
- Contact lenses
- Eye surgery (when was it done, where and by whom)
- Eye laser (what was it for)
- Eye drops (prescribed or over-the-counter)
- Whether the patient is known to an ophthalmologist or ophthalmology department
- When, where and who last saw the patient and what problems were being managed

Consider the following when conducting an eye assessment:

- Demographics are crucial to the diagnosis of many ophthalmic conditions. An ophthalmologist will often ask you to go back and clarify a patient's age before moving on to the details of the presentation.
- The most common reasons for patients to present with ophthalmic problems are listed above. Determining which of these is relevant to the patient will focus your clinical assessment and discussion with the ophthalmologist. Be aware that this is a simplified approach and there may be multiple reasons, such as visual loss following trauma, or there may be another symptom.
- Patients often confuse optometry and ophthalmology, so be careful to make this distinction yourself. If the patient refers to advice given by their 'eye doctor' clarify exactly who they mean and what advice was given.



Take note of drops that may have been prescribed by a GP or an optometrist in the recent past. Steroid drops are occasionally prescribed for red eyes but can cause blinding complications when used inappropriately. Steroid eye drops should only be prescribed following a comprehensive ophthalmic examination and in situations where close ophthalmic follow-up can be provided.

- Ask if the patient drives and in what capacity.
- Ask if the patient is a carer for someone else, or if they are cared for themselves.

Notes

You must specifically ask if the patient has had any eye surgery, laser or injections. Remember that the patient may not volunteer the information because they may not deem it relevant, but it may be crucial to diagnosis.

Because many ophthalmic procedures are done on an outpatient or day surgery basis, with regional anaesthetic, and can be very rapid, patients may omit to mention them simply because they have forgotten. This is particularly the case if the procedure was performed many years ago without complication.



Intravitreal injections are the modern standard of care for certain types of macular degeneration, diabetic macular oedema and other ophthalmic conditions, and hence are very common. This treatment entails regular injections, sometimes monthly, and prevents blindness in many thousands of patients. It also exposes patients to the rare but devastating complication of intraocular infection (endophthalmitis) following injection. Any patient presenting with ophthalmic symptoms following an intravitreal injection requires urgent ophthalmic review.

Although the most common ophthalmic operation is cataract surgery, there are many different operations that a patient may have had, including retinal detachment surgery, surgery for glaucoma or corneal transplantation. It is very helpful if the patient can tell you what they have had, so try to elicit these details.

Visual loss

- When it occurred
- What the patient was doing
- What has happened since the visual loss

Ask the patient to describe the following:

- Total 'black out' or 'blurry'
- Intermittent or constant
- Whole or part of the visual field
- One or both eyes
- If the eyes are painful or painless
- Are the eyes red or white
- Preceding flashes/floaters OR brief episodes of visual loss
- Any similar previous episodes

Consider whether the patient has associated symptoms, such as:

- Headache
- Nausea or vomiting

Notes



Visual loss is potentially very serious and should be accorded an appropriate level of concern.

Of the numerous potential causes of visual loss, some can be elucidated with the above questions.

For example:

- Rapid, painful visual loss in a red eye with associated headache and vomiting may be due to an angle closure crisis (angle closure glaucoma).
- Sudden vision loss in one eye that was preceded by intermittent episodes in the

hours or days prior may be amaurosis fugax, heralding an impending cerebrovascular accident or anterior ischaemic optic neuropathy due to giant cell arteritis (GCA).

- Visual loss in one or both eyes that is accompanied by headache may be due to GCA or elevated intracranial pressure.
- Visual loss preceded by flashes/floaters may be due to a retinal detachment.

If you are concerned about a neurological cause for visual loss, it is reasonable to proceed with appropriate neuroimaging prior to contacting an ophthalmologist. An ophthalmologist may help with the diagnosis of some neurosurgical emergencies but cannot treat them.

Flashes/floaters are a common reason for presentation and may indicate the presence of a retinal tear or may be innocuous. There is no way to make this distinction from the patient's history. Therefore, a patient with flashes/floaters should be regarded as having a retinal tear until proven otherwise. This requires a detailed examination of the peripheral retina by an ophthalmologist with specialised equipment and is beyond the scope of an emergency department (ED) assessment.

Patients may not notice loss of vision in one eye and only come to realise this sometime later when the good eye is covered for another reason. This is not common, but can occur once other causes of acute visual loss have been excluded.



Abrupt vision loss in any patient over 50 years of age mandates consideration of giant cell arteritis (GCA) (see next).

Double vision (diplopia)

- Double vision (diplopia) can be a confusing symptom for both the patient and the doctor.

Keep it simple by working through the following questions:

- Is it only present with both eyes open?
- Is it present if one eye is closed? If so, which eye?

If double vision is only present with both eyes open, consider whether:

- the two images are side-by-side, on top of each other, or vertically displaced
- the double vision resolves if the patient looks in a particular direction
- the double vision gets worse (greater separation between the images) in another direction.

Notes

- Consider whether it is truly double vision, as opposed to one eye's blurred image superimposed on the other eye's clear image. This would suggest that visual loss or blurring is the real issue.
- Binocular diplopia occurs if the double vision is only seen with both eyes open. This usually means that the eyes are misaligned due to an imbalance of the extraocular muscles.



Binocular diplopia is an emergency as it may indicate a cranial nerve palsy due to intracranial pathology, for example, a third cranial nerve palsy caused by an aneurysm of the posterior communicating artery. Pay close attention to the presence of eyelid ptosis, pupil changes, concurrent headache and other neurological symptoms, and proceed with urgent neuroimaging if you deem it appropriate.

Binocular diplopia in any patient over 50 years of age mandates consideration of giant cell arteritis (GCA) (see next).

Other common causes of diplopia are other cranial nerve palsies, myasthenia gravis, thyroid eye disease and periorbital fractures, so look for the clinical signs associated with these disorders.

Painful or red eyes

Ask the patient the following questions:

- Has the patient had recent intraocular surgery, laser or intraocular injections?
- Does the patient wear contact lenses? If so, has the patient been swimming with, sleeping with or overwearing the contact lenses?
- Does the patient have decreased vision?
- Did the patient experience any prior trauma, foreign body or flash from welding?
- What is the duration of symptoms?
- Does it affect one or both eyes? One eye then the other?
- Are the eyes itchy?
- Is there discharge?
- Do family members or other contacts of the patient have a red eye?
- Has the patient experienced any prior similar episodes? If so, were they investigated and what was the cause, if known?
- Has the patient had prior herpetic eye disease?
- Does the patient have any cold sores or need for prior acyclovir?
- Does the patient have any systemic symptoms such as rash, arthritis or urethritis?

Notes



An urgent ophthalmic referral is mandatory if a patient presents with symptoms following a recent ophthalmic procedure, especially any eye surgery or intravitreal injection (injection into the eye).

Similarly, any contact lens wearer with red or painful eyes (or visual changes) warrants an urgent ophthalmic review.

Discharging, red eyes in a neonate within one month of birth is an ophthalmic emergency and requires immediate input from ophthalmology, paediatrics and infectious diseases.

- Red, painful eye(s) associated with visual loss may be due to acute angle closure crisis, corneal infection, severe intraocular inflammation, (e.g. iritis) or intraocular infection (endophthalmitis).
- The presence of discharge usually indicates a viral, bacterial or allergic conjunctivitis.
- Herpetic eye disease tends to be recurrent and can be associated with significant corneal scarring and visual impairment. Patients may be aware of the presence of corneal scars or that they needed topical (or systemic) antivirals in the past. Patients with herpetic eye disease often need chronic low-dose topical steroids or prophylactic systemic antivirals, which may be a clue to their diagnosis.

Trauma or chemical injury

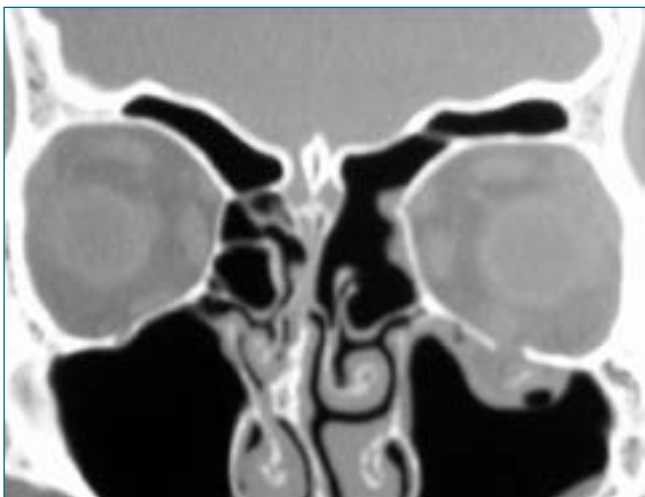


If a chemical injury is suspected, postpone further history-taking or examination and immediately begin irrigation of the eye(s).

Ask the patient the following questions:

- What time did the trauma/chemical injury happen?
- Where did it happen?
- What was the mechanism?
- If a chemical injury is suspected, what was the chemical?
- If a foreign body is suspected, what does the patient think it might be?
- Was the patient doing any grinding or other industrial activities before eye symptoms?
- Was any plant or organic material involved?
- Were the patient's glasses or any protective eyewear worn?
- How has vision been affected since the injury?

Figure 1. White blow-out fracture.



Notes

Ophthalmic trauma and chemical injuries are potentially blinding. Because of this, the normal sequence of history and examination is sometimes suspended.



In the case of a chemical injury, check the pH and immediately begin copious irrigation until the pH is normal. This is one situation in which you do not need to check visual acuity in the acute stage. Find out what the chemical was, whether it was acid or alkali and liaise with the Poisons Information Centre (131 126) for further information.



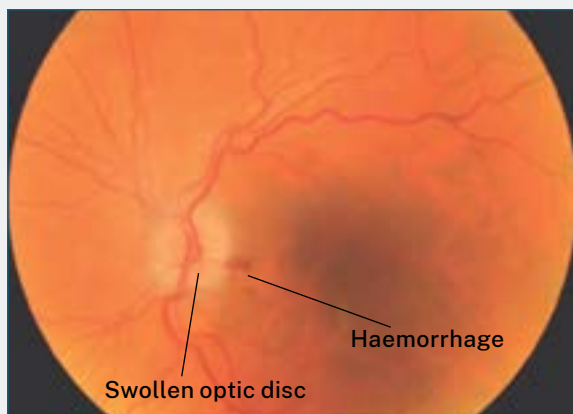
Globe ruptures can occur following serious or seemingly innocuous injuries and from both blunt or penetrating trauma. If you suspect a globe rupture, stop examining the patient and immediately apply a clear shield over the eye. Do not clean the eye or perform any manipulation, as this can worsen the injury. However, you must still check the visual acuity.



Retrobulbar haemorrhage is usually dramatic and readily apparent from an examination. It is a clinical diagnosis, and you must check visual acuity. If suspected, liaise urgently with an ophthalmologist who can perform emergency lateral canthotomy and lower lid cantholysis. This can sometimes also be performed by plastic and maxillofacial surgeons or ED physicians, depending upon the skill set possessed.

- If the eye has been scratched, determine whether organic material was involved as this increases the risk of infection, especially fungal keratitis.
- Always document the mechanism of any eye injury carefully, as it may have medicolegal implications. If there is a chemical injury, document whether the exposure happened at work or in the home.
- Be specific about the type of eye protection worn at the time of injury, including the patient's own glasses, specialised protective spectacles or protective goggles.
- Glasses worn at the time of trauma can shatter and pieces of the lens or frame may contribute to ocular injury. Maintain a low threshold of suspicion for penetrating eye injury and, if possible, ask to examine the glasses that may have been brought to hospital with the patient.

Figure 2. Swollen optic disc and haemorrhage.



AION due to giant cell arteritis

Consider the following in determining if the patient has giant cell arteritis (GCA):

- Abrupt, painless loss of vision in one or both eyes
- Brief, transient visual loss in hours or days prior
- Double vision
- Headache (classically frontotemporal)
- Jaw or tongue claudication (worse with chewing or talking)
- Discomfort on brushing hair over one or both temples
- Weight loss
- Anorexia
- Polymyalgia rheumatica symptoms (pain and stiffness in pelvic or shoulder girdles)

Notes



Suspect giant cell arteritis (GCA) in any patient over 50 who presents with visual changes or a cranial nerve palsy.

- You may have already considered GCA if the patient has visual loss or diplopia, but take the opportunity to consider the diagnosis again prior to contacting an ophthalmologist.
- GCA can present insidiously and rapidly progress to bilateral complete blindness, in some cases despite adequate treatment.

- The diagnosis of GCA is largely clinical, i.e. it is based on history and supplemented with inflammatory markers, and only later by a temporal artery biopsy. Treatment is usually undertaken in the presence of compelling history, regardless of inflammatory markers.
- If you suspect GCA, liaise urgently with an ophthalmologist. Referrals to endocrinology or rheumatology may also be appropriate in certain clinical scenarios.
- Jaw (or tongue) claudication can be differentiated from other causes of dental or temporomandibular pain by determining that (as with all claudication) there is no pain at the beginning of mastication, and that pain develops after a specific amount of time, abates after cessation of chewing and recurs upon resumption.
- Document symptoms specifically and in point form, (e.g. 'no headache, no jaw claudication, no tongue claudication') rather than simply writing 'no GCA symptoms' as this might be challenged subsequently.
- The relevant clinical signs to elicit on examination in suspected GCA are: tenderness over the superficial temporal arteries or paucity of pulsation on one or the other side and the presence of a relative afferent pupillary defect (RAPD). In acute GCA, the optic disc may be pale and swollen, and while an effort may be made to visualise the optic disc, this is normally outside the scope of an ED examination.

Assessing the severely injured patient

Although life-threatening injuries take priority over the assessment of the eye, it is not acceptable for severe ocular injury to go unrecognised in a multi-trauma patient once life-threatening issues have been stabilised.

There are two main reasons for including an eye assessment in the assessment of relevant trauma patients:

- Firstly, damage to the eye can become the defining injury for a patient who has survived severe trauma, irrespective of the other injuries they sustained. Hence, it is important to be aware of these injuries early so that they can be addressed appropriately.
- Secondly, although rare, some ocular injuries are amenable to timely intervention that can sometimes restore vision, e.g. retrobulbar haemorrhage and chemical injury. Missing these entities can contribute significantly to a patient's morbidity.

Technique

Checking visual acuity in recumbent or restrained patients or those in cervical collars can be difficult, but this is vital if an ophthalmic injury is suspected.

Strategies include the following:

- Use another staff member to occlude the other eye or hold a pinhole.
- Lower the patient's bed without compromising immobilisation of the spine.

- Hold a 3m chart above the patient's bed. Ensure your safety first and foremost and adhere to work health and safety regulations.
- Permanently tape a 3m or 6m chart to the ceiling after measuring the distance between the bed (putative position of the eyes) and the ceiling. The acuity readings can be calibrated based on the distance you have measured, e.g. an eye that just sees the largest 'E' on a 6m chart (labelled '60') from a 2m distance should be recorded as '2/60'.

While it is not possible to check visual acuity in obtunded or intubated patients, you must still undertake the following:

1. Perform a general inspection of the globe:
 - check the integrity of the globe for rupture
 - examine without putting pressure on the eye
 - check for retrobulbar haemorrhage
 - check for a bulging, tense, proptotic eye with an inability to close the eyelids
 - check for periocular and eyelid lacerations.
2. Check pupillary reactions for:
 - direct and consensual pupil reaction
 - RAPD and pupil size

This is the most important source of information in obtunded patients (remember that the room must be temporarily darkened to assess this).

Paediatric assessment

Paediatric assessment can be very difficult, particularly if the child is injured or distressed. Do not delegate the task of assessing a child to a junior or an inexperienced member of the ED team and do not separate the child from their parent(s) during the assessment.

History

- Find out the child's age, vaccination and fasting status.
- Obtain a detailed history from an adult witness.
- A lot of information can be gathered by simply observing the child while you take their history.
- Assess visual acuity for each eye based on the patient's age and ability to interact. Although this can be difficult, it is vitally important and cannot be deferred. Enlist the parent's help for an explanation, covering an eye or holding a visual target. Check visual acuity before the child becomes distressed, as may happen when you examine them.
- Check visual acuity as appropriate for each age group.

Babies

Assess the ability to fix and follow light and blink in response to bright lights (use a target with a central, steady and maintained gaze). A small child will fix and reach for a bright object.

Toddlers

Assess the ability to identify and reach for a small coloured target (e.g. single 100s and 1,000s sprinkles or similarly sized rolled up piece of paper). Sprinkles (e.g. 100s and 1,000s) are commonly used to test fine vision in children.

Infants

Assess visual acuity using a shape (or Snellen) chart using a matching board ('tumbling-E's).

Age 5 or older

Assess using Snellen acuity test. Check pupils and for an RAPD.

Some eyedrops will sting upon instillation. Topical anaesthetic, although initially painful, can be very useful as it will relieve pain for about 20 minutes and may allow the child to spontaneously open their eye after a few minutes.

It may be necessary to gently restrain a child to facilitate examination, or it may be feasible to sedate the child in the ED, provided staff with the appropriate training are available. In some cases, it is necessary to plan an examination under anaesthesia to complete the assessment.

Notes

If a history is unavailable, always suspect an injury or foreign body as a cause for a red or painful eye in a child. If you suspect non-accidental injury (NAI), contact the relevant child protection service in your area.

Periorbital cellulitis can be more aggressive in children than in adults. It is normally treated by admitting the child and placing them on intravenous antibiotics under ophthalmology and paediatric care.

Conjunctivitis in any child within one month of birth is a medical emergency and requires input from ophthalmology, infectious diseases and potentially the child protection unit.

As is true for adult patients, do not put any pressure on an eye that you suspect may be ruptured. This is particularly an issue in children where examination can be difficult. If you suspect a globe rupture, put a shield on the eye, fast the child and contact ophthalmology.

Orbital floor fractures in children are more likely to adopt a greenstick configuration and entrap part of the inferior rectus without significant external signs of injury. Be wary of the classic presentation of the white-eye blow-out fracture – a child presenting following blunt periocular injury with an uninflamed white eye and inability to look up. They may be quite unwell if they have a concurrent oculocardiac reflex (which is more common in children) and this can provoke nausea, vomiting and fatal bradyarrhythmias.

A child presenting at any age with no red reflex is said to have leukocoria. This may be noticed by the parents, following a photograph that has been taken, or by an optometrist. Several very serious pathologies must be excluded in this situation, chiefly retinoblastoma. Leukocoria requires urgent ophthalmic assessment.

As discussed in the visual acuity section, amblyopia is a common cause of reduced vision in adulthood. It occurs due to some sort of visual impairment in children and cannot be treated beyond approximately 10 years of age. If you discover unequal vision in a child whose vision you have checked, the child may have amblyopia that is still amenable to treatment. Contact ophthalmology to arrange an examination within 1–2 weeks.

Examinations

Examination essentials

Assessment of ophthalmology patients follows the same basic pattern of history and examination as in every other area of medicine.

Below is a brief checklist for history and examination that should be used when assessing patients with ophthalmic complaints. Please refer to it before contacting an ophthalmologist to ensure you have addressed all the major points. The subsequent sections provide more information on each specific area.

Key points

Consider the following in examining patients:

- Take a history, check visual acuity, perform a general inspection at arm's length and look for an RAPD for all patients.
- Selected other examinations may be appropriate.
- It is usually not necessary to dilate pupils in ED. Only dilate a patient's pupils after you have spoken with an ophthalmologist (and in cases of trauma, the neurosurgery team).

History

- Age
- Basic demographics
- Medical history

Reasons for presentation

- Visual loss
- Diplopia (double vision)
- Painful or red eyes
- Trauma or foreign body
- Flashes and floaters
- Glasses/contact lenses/eye drops
- Prior or recent eye surgery/laser/injections

Examination

Essential

1. Visual acuity
 - Without and with a pinhole for each eye
 - 6/5 to 6/60, counting fingers (CF), hand movements (HM), perception of light (PL) or no perception of light (NPL)




Figure 3. Snellen chart using 6m eye chart (visual acuity ratio in red).

2. General inspection
 - Periocular injuries or injury to the globe
 - Eye red or white
 - Ptosis, proptosis or obvious misalignment of the eye
 - Gross surface anatomy of the orbit, lids, lashes and eye

3. Pupils
 - RAPD
 - Direct and consensual response for each eye
 - Size, shape and reactivity to light
4. Red reflex with a direct ophthalmoscope

Essential in patients with visual loss or change or neurological complaints

5. Visual fields
6. Eye movements
7. Cranial nerve examination

Additional

8. Slit lamp examination
9. Examination with direct ophthalmoscope



Contact an ophthalmologist immediately after your assessment if you suspect these conditions:

- Giant cell arteritis (GCA)
- Endophthalmitis
- Penetrating eye injury
- Retrobulbar haemorrhage
- Severe chemical injury
- Ophthalmia neonatorum
- Acute angle closure glaucoma
- Pain, redness or decreased vision in an eye after any intraocular procedure (surgery or injection) or in a contact lens wearer
- Ophthalmic symptoms in any patient with only one eye (includes prosthetic eye or long-standing poor vision in the other eye)

Until proven otherwise

- Flashes and floaters = retinal tear
- Visual loss, visual change and diplopia in a patient >50 years of age = GCA
- Serious periocular trauma = ruptured or penetrated globe
- Serious periocular trauma = associated intracranial injury
- Periocular lacerations contain a foreign body
- Eyelid lacerations are full thickness and involve the globe

Reasons to defer visual acuity testing

- Chemical injury
- Obtunded, intubated or unconscious patient
- Severe life-threatening injury or neurological concern

Diagnoses of exclusion

- Poor vision due to amblyopia
- Poor vision due to prior visual loss that has only just become apparent to the patient

Reasons not to dilate a pupil

- Will not allow subsequent assessment for an RAPD
- May precipitate angle closure
- Situations of head injury (will obviate pupil measurements if the patient needs neurological observations)

General inspection and assessment of periocular and globe trauma

A general inspection provides a wealth of information on all patients, particularly after trauma. Most external eye findings can be seen with a bright pen torch or direct ophthalmoscope. Examine the eye in an orderly fashion, i.e. lids, conjunctiva, cornea, iris, pupil, anterior chamber, lens.

Address the following questions:

- Is the eye red or white?
- Is the globe ruptured or penetrated?
- Are there signs of retrobulbar haemorrhage?
- Are there periocular lacerations and ecchymoses?
- Are there signs of cranial nerve palsy?
- Is there cellulitis or swelling of the eyelids or skin around the eye?
- Is there a foreign body in the lids, eye or orbit?

Remember that in all serious trauma to the eye, a penetrating eye injury and concurrent intracranial injury must be excluded.



1. Is the globe intact?

Always begin with observation (see questions above) and check visual acuity, eye movements and pupils.

If you suspect globe rupture or penetrating eye injury, examine with the utmost care. Do not put any pressure on the eye. Gently distract the eyelids by pressing **ONLY** on the orbital margins.

External clues:

- Missile protruding from the eye: do not remove it or touch it
- Swollen, haemorrhagic eyelids
- Obvious prolapse of uveal contents
- Distortion of the cornea or the globe
- Circumferential conjunctival swelling and haemorrhage
- Complete '8-ball' hyphaema

If you confirm globe rupture, do not examine any further. Put a clear plastic shield (or other makeshift mechanical protection) over the eye, avoiding pads or anything that might come in contact with the eye. Contact ophthalmologist. Any pressure put on the eye will exacerbate the injury.



2. Is there a retrobulbar haemorrhage?

External clues:

- Bulging, tense or proptotic eye with an inability to close the eyelids following blunt trauma

Check visual acuity and for an RAPD. The presence of a periorbital fracture does NOT preclude a retrobulbar haemorrhage.

Retrobulbar haemorrhage is a clinical diagnosis and does not need imaging for confirmation. If you suspect it is present, liaise urgently with an ophthalmologist, emergency physician or a plastic or maxillofacial surgeon to perform canthotomy and lower lid cantholysis.

For eyelid lacerations, document which eyelid and location (medial, middle or lateral third). Eyelid lacerations must be assumed to be full-thickness, (i.e. through-and-through) until proven otherwise.



Severe eyelid lacerations may result in the inability to close the eye and protect the ocular surface. In such situations blinding corneal exposure can rapidly occur.

Notes

- Lacerations involving the eyelid margin need specialised repair.
- Lacerations involving the medial-most portion of the eyelid may also involve the lacrimal canaliculus and need specialised repair.
- Periorbital cellulitis may complicate lacerations, in this case, document the extent of erythema.

3. Are there periocular ecchymoses ('black eye') and inflammation?

External clues:

- Document presence and extent

Take note of any localised eyelid swellings which may indicate abscesses or chalazia.

Bilateral periocular ecchymoses in a head trauma patient is suggestive of a base of skull fracture.

4. Are there periocular and eyelid lacerations?

External clues:

- Document number, size, location and depth
- All periocular lacerations must be assumed to have a foreign body until proven otherwise

5. Documentation

For external clues, draw a diagram and provide accurate measurements at the initial assessment.

Note whether any lacerations have been sutured prior to your assessment. Facial scarring can be very disfiguring and patients may not be aware that scarring will result, so it is important to explain this and document that you have had this discussion.

In accordance with NSW Health policy, in emergency situations a personal device can be used to capture and store relevant clinical images due to the urgent need for care, treatment or advice. Images should be transferred to the local health records management system as soon as practical and the image permanently deleted from the personal device.

6. Imaging

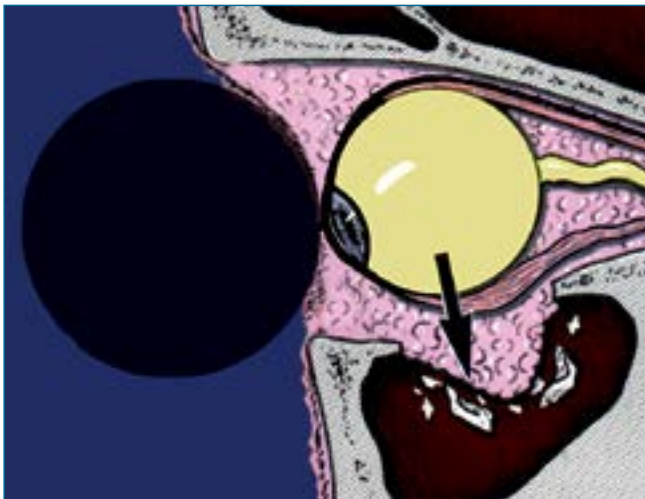Imaging is very important following periocular trauma for the diagnosis of periorbital fractures and to define globe and soft tissue injuries. Computed tomography (CT) imaging is often the preferred modality in orbital pathology.



If a periorbital fracture is present with entrapment of extraocular muscles, be alert to the possibility of the oculocardiac reflex which can cause life-threatening bradyarrhythmias.

In all serious periocular trauma, consider that the patient may also have intracranial trauma. Examine, image and liaise with other specialties accordingly.

Figure 4. Orbital floor fracture.



7. Cranial nerve palsies

Consider the following:

- Perform a cranial nerve exam as you would normally.
- See the relevant sections for specific assessment of pupils, visual field (for second cranial nerve/optic nerve) and ocular movements for third (3rd) and sixth (6th) cranial nerves.
- Signs of a 3rd cranial nerve palsy include ptosis on one side, an eye that is misaligned downward and laterally, and a dilated pupil.
- Signs of a unilateral or bilateral 6th cranial nerve palsy include misalignment of the eye(s) medially, in addition to the inability to abduct the eye(s).
- Signs of a seventh (7th) cranial nerve palsy include the inability to close the eye and drooping of the lower eyelid and corner of the mouth.

Visual acuity

Visual acuity provides the most important information about how an eye is functioning and is the basic means of examining an ophthalmology patient. It is analogous to blood pressure measurement or an electrocardiogram (ECG). Visual acuity must be checked in any patient with an ophthalmic complaint or periocular injury.

Visual acuity assessment is not complete unless the following are performed:

- Checked in each eye separately
- With the patient's distance correction (distance glasses)
- Without then with a pinhole
- Documented in notes

Technique

Visual acuity assessment can be confusing, so keep it simple.

1. Sit the patient 6m away from the chart or 3m away from a mirror that is reflecting a chart positioned above their head, thus creating an optical 6m. Make sure that the chart is illuminated (either room lights are on, or the globe is turned on behind the chart if it is a retro-illuminated chart).
2. Ask the patient to put on their distance glasses (the glasses they use for driving, not reading). If you are unsure, try with and without; distance glasses will improve the patient's distance vision.
3. Use a solid object to occlude one eye. If the patient is using their hand, ask them to hold the palm of their hand gently up against their eye, rather than their fingers, as it is possible to peek through fingers.

Options to ensure the eye is fully occluded:

Figure 5. Correct.

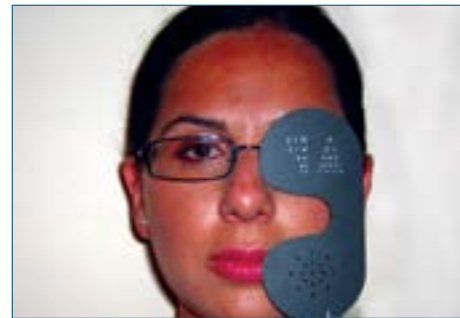

Figure 6. Correct.



Figure 7. Correct.

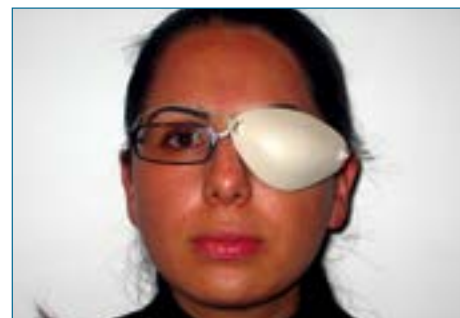
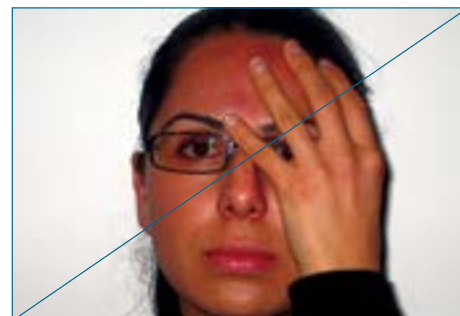
Figure 8. Incorrect: beware of peeking!

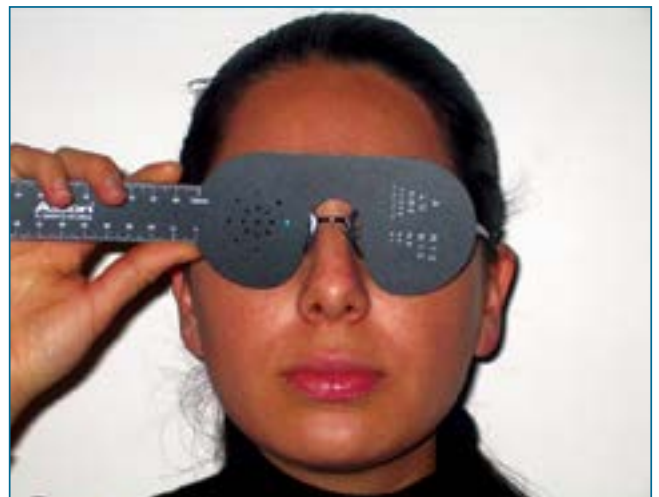

4. Ask the patient to read as low down on the chart as they can. Don't correct the patient if they make a mistake. Provide encouragement irrespective of whether they are correct or incorrect. Don't let the patient give up once things become blurry, instead encourage them to keep going. It is not uncommon for patients to give up several lines above their actual acuity because it is blurry. Push them to get as low as possible on the chart. A patient's visual acuity is defined as the line where they correctly guess $\geq 50\%$ of the letters, whether they appear blurry or not.
5. Document as you go, using the following convention: the number '6' over the number of the lowest line that the patient can read (that is, 60, 36, 24, 18, 12, 9, 6, 5), giving you the familiar fraction (6/60, 6/36, 6/24, 6/18, 6/12, 6/9, 6/6, 6/5). 'RVA with glasses + pinhole is 6/18' is equivalent to saying that your patient, with distance glasses and a superimposed pinhole, can see at 6m what a normal person can see at 18m (6/18, which is a fraction less than 1, can be thought of as less than normal vision). The top number refers to the testing distance, (e.g. 6) and the bottom number refers to the size of the letters the patient sees (e.g. 6, 9, 12, 18, 24, 60).
6. Now test the eye looking through a pinhole. Use an occluder with a pinhole, or, if not available, poke a hole in a piece of paper with a 19G needle (or even the tip of a pen). Look through it yourself before giving it to the patient to ensure that the aperture is clear. You may be surprised to note that your vision improves as well. Do NOT attempt to make a pinhole while the patient is holding the paper over their eye. Ask the patient to read the chart again and record the pinhole acuity as above.
7. If the patient cannot read the largest line on the chart, test if they can count how many fingers you are holding up in front of their eye. Test progressively at 30cm, 1m, 2m and 3m. If possible, record vision as CF and the distance at which you measured.
8. If the patient cannot count fingers, assess whether that eye can see your hand moving. Wave your hand back and forth in front of their eye at 30cm or more. If you are too close, they may perceive light flickering, feel the air movement on their face or hear your bracelets, rather than see your hand moving. Ask the patient to either describe the direction your hand is moving or mirror the movement with their hand. If possible, record vision as HM.
9. If the patient cannot perceive hand movements, darken the room lights, ensure the other eye is completely occluded and shine a bright light into the eye from about 10cm. Ask if they can see it. Shine the light on and off the eye repeatedly and ask the patient to identify when the light is on their eye. If they can, vision can be recorded as light perception (LP or PL). If they cannot, it is recorded as no light perception (NLP or NPL).
10. Repeat the same process with the other eye.



[Video - How to measure visual acuity](#)

Figure 9. Pinhole occluder.



Notes

Visual acuity must be checked for every patient with an ophthalmic complaint or periocular injury. It is of vital importance for assessment and prognosis. There are instances in which visual acuity assessment can be deferred, e.g. acute chemical injury, where irrigation takes priority, or in severe life-threatening trauma where attending to life-threatening injuries takes priority. However, in both cases, visual acuity must still be assessed at some stage to ensure severe eye injuries are not missed.

Visual acuity must be documented in your notes. Avoid writing 'normal visual acuity' or 'blind' as this does not provide any objective information. Instead, record the specific acuity in each eye without, then with, a pinhole. If this is omitted, or the specific acuity is not documented, the statement 'normal visual acuity' can subsequently be challenged. This is particularly an issue during handover in EDs, where a colleague may have claimed to check visual acuity but not recorded it.

It is unacceptable to say that a patient has 'normal' or '6/6' vision because they can read newspaper print, the writing on an IV bag, the lowest line on a handheld chart or anything other than the 6/6 line on a Snellen chart that is 6m away. Similarly, documenting vision as counting fingers because that is all you have checked and you do not have an acuity chart means that the patient's vision has not been examined. It may be tempting to do these things because measuring visual acuity using a chart can be inconvenient, but it means visual acuity has not been correctly checked, and there can potentially be serious medical and medicolegal repercussions.

A vision of 6/6 does not preclude serious ocular pathology.

Test the eye that you suspect to have poorer vision first, to lessen the chance that the patient will remember the letters when you test the other eye. Observe the patient carefully during the test to ensure that they are not looking around the occluder or their hand or peeking in another way. Visual acuity testing is an objective test and the patient can either read the letters or not, irrespective of whether they are subjectively blurry or clear.

A patient must get at least 50% of the letters correct on each line to be credited with that acuity. It is possible to record mistaken letters (on a line that was achieved) with a superscript of -1, -2 or -3, or extra correct letters on the next line (if the whole line was not achieved) with a superscript of +1, +2 or +3 next to the visual acuity. For example, you may record the acuity as 6/12-1.

Patients may not know which glasses you mean when you ask them to put on their 'distance glasses'. You can be more specific by asking which glasses they use to drive or watch TV. If there is still confusion, simply test the vision with and without each pair. Multifocal glasses provide distance correction when looking through the top segment and near correction when looking through the lower segment. Ensure that the occluder used for the other eye is not pushing multifocal glasses up the patient's nose, causing them to look through the glasses' reading segment.

A pinhole works by eliminating spherical aberration, or the poorly focused rays of light that are refracted at the periphery of a lens (in this case, the eye's tear film, cornea and lens). A pinhole eliminates most refractive error and approximates a 'universal' lens, and this gives vital information about an eye's best possible vision. Visual acuity testing is not complete until pinhole acuity for each eye is tested and recorded. Remember that visual acuity testing should be done with glasses and then with a pinhole as well. It is a common misconception that testing with glasses and with a pinhole are mutually exclusive. If a patient's distance glasses have not been updated for some time, they may have significantly better acuity when tested with a pinhole as well.

'Normal' visual acuity or 6/6 means that the patient can see at 6m the same target that a person with normal vision can see at 6m. As the denominator increases, the visual acuity decreases, so a vision of 6/60 means that while a person with normal vision could see the target at 60m, the patient can only see it at 6m. Similarly, 6/36 vision means that while a person with normal vision could see the target at 36m, the patient can only see it at 6m.

The distance to the chart is of paramount importance. If the chart is closer, it will give an inaccurate visual acuity. While it is possible to mathematically adjust the ratio to reflect a shorter viewing distance, this adds an unnecessary level of complexity to an ED assessment. Keep it simple and check at 6m (either directly or reflected in a mirror).

Near acuity (or reading vision) as checked with a handheld chart or a mobile phone app is an alternate means of checking acuity but is NOT

readily interchangeable with distance acuity. Snellen distance acuity is the standard method of measuring a patient's acuity and has the most clinical relevance. It can create confusion if a different method is used, particularly when the acuity on presentation in ED is needed for comparison at later stages in the patient's assessment.

An alternative to using a wall-mounted chart is a scaled, handheld paper chart that is held at 3m. This is particularly useful for examining bed-bound or recumbent patients. However, it is more prone to inaccuracy as it is difficult to calibrate exactly 3m from the patient's eye and charts that have been photocopied suffer a degradation in contrast which can also artificially degrade visual acuity. Many of these charts are also inaccurately labelled concerning the visual acuity corresponding to each line.

Patients who do not recognise the common Snellen letters can be tested with the 'tumbling-E' chart. This replaces Snellen letters with the letter 'E' in four different orientations: up, down, left or right. The patient is asked to point in the direction that the 'E' is pointing on the chart.

If a patient is in pain, it is reasonable to instil a drop of local anaesthetic to facilitate checking visual acuity. Give the patient a few minutes after anaesthetic instillation for the eyelid spasm to subside.

Although amblyopia is a common cause of unilateral poor vision in adults, do not attribute reduced vision in ED to amblyopia. It is a diagnosis of exclusion. Amblyopic eyes are as prone to pathology as non-amblyopic eyes, and,

in some cases, more likely to be injured. Be especially attentive if a patient describes further worsening of vision in an eye that was suspected to be amblyopic.

A vision of NLP has an extremely poor prognosis and tends only to occur in the very end stage of diseases such as glaucoma, retinal detachment, injury to the optic nerve or following serious injury. While you may encounter patients in whom an eye has been NLP for some years, if an eye suddenly becomes NLP, then very serious pathology is present. In patients over 50 years old, abrupt loss of vision to NLP means GCA until proven otherwise. Liaise with an ophthalmologist and commence treatment to prevent a similar occurrence in the other eye.



Common pathologies such as cataracts, vitreous haemorrhage and amblyopia do not cause vision of NLP. The instances in which an eye recovers some vision after having been NLP are very rare.

Pupil examination

Pupil examination is a vital part of both the ophthalmic and neurological assessment. It must be done in all patients. In obtunded or severely injured patients it may be the only type of examination possible other than general inspection and fundoscopy.

Pupil examination is not complete unless you have assessed for an RAPD.

If a pupil abnormality is detected, you must also examine the patient's eye movements, eyelids and visual field.

Key aspects of pupil examination are size, shape and reactivity. In ambient light, both pupils should be of equal size and shape. Physiological anisocoria is present in up to 15% of the population and does not imply an RAPD.

Technique

Pupil examination technique requires the following:

1. Observe pupil size in the light. Ask the patient to look at a target behind you, so that there is no accommodation on a near target which will influence the size of the pupils. Look for a difference in pupil size (anisocoria), difference in iris colour (heterochromia) or irregularity of the normally round shape.
2. Darken the room and check pupil size again. Note whether any difference in pupil size is more pronounced in the light or the dark.
3. Shine a bright light into one pupil and observe it constricting to assess the direct pupil response on that side.

4. Check that the other eye also constricts to assess the consensual light reflex. Repeat this process by shining the light into the other eye.
5. Check for an RAPD. Shine a bright light into one pupil for 2–3 seconds, then rapidly flick the light across to the other side, and hold it for the same duration. An RAPD is present if the pupil initially dilates (instead of initially constricting) when flicking across from the other side. You can go back and forth several times until convinced of the findings, provided that the time over each eye is the same and the time in between the eyes is very short.



[Video - How to examine an RAPD](#)

Notes

Although an RAPD may be subtle in some cases, it is a vitally important clinical sign to elicit in situations of sudden visual loss and ophthalmic trauma.

When pupils have been pharmacologically dilated, it is not possible to test for an RAPD. This is one of the principal reasons that pupils are not dilated in ED prior to ophthalmic assessment.

The key to detecting an RAPD reliably is to ensure that each eye is exposed to the same amount of bright light for the same amount of time, with the briefest possible transit between each eye. It is possible to mistakenly give the impression of an RAPD if the light intensity or the time over each eye varies.

The principle behind an RAPD is that by alternately presenting each eye with a symmetrical, intense light source, a subtle unilateral optic nerve defect will be exposed. If the optic nerve is damaged on one side, when the light flicks to that eye, the direct response is less than the consensual response from the recent contralateral light stimulation, and so the pupil is observed to dilate. It should be noted that this observation is based on the direct and consensual pupillary reflexes being equal in amplitude.



Vision loss in giant cell arteritis (GCA) (or any other cause of optic neuropathy) is associated with a relative afferent pupillary defect (RAPD).

It may be hard to assess pupil size in the dark if the patient has a dark-coloured iris. Experiment with using a diffuse light shone from above or below that allows you to see the pupil without influencing its size or with a single-flash camera.



Remember that a unilaterally dilated pupil on one side may indicate an acute third (3rd) cranial nerve palsy and urgent neuroimaging and liaison with a neurosurgical service is required if detected.

There are many situations in which pupils may be abnormally shaped, including intraocular inflammation, prior surgery or accidental trauma.

Swinging torch test

This involves demonstrating a left relative afferent pupillary defect where the left pupil dilates after prior consensual constriction with direct light stimulation of the right eye.

Figure 10. Swinging torch test (consensual constriction).

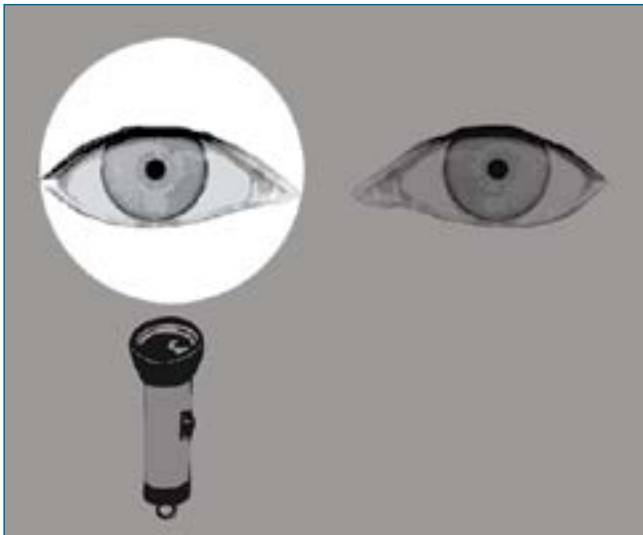
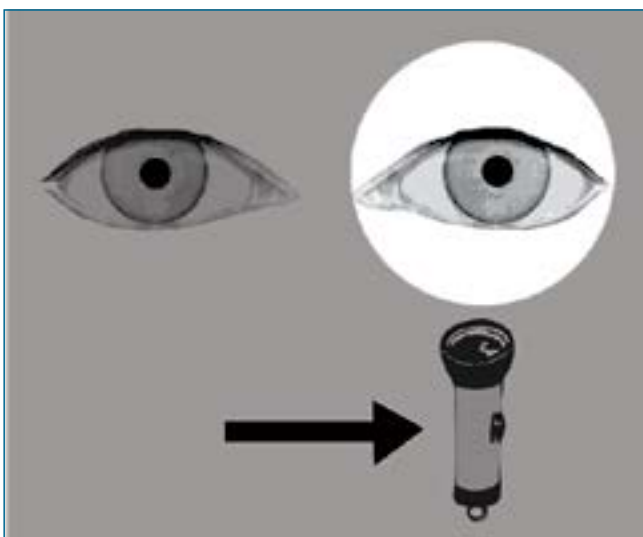


Figure 11. Swinging torch test (left pupil apparent dilation).



Visual field, eye movements and eyelid examination

Visual field, eye movement testing and eyelid examination are not mandatory in all ophthalmic patients (for example, a simple foreign body) but must be tested in anyone with visual changes or suspected optic nerve, orbital or neurological pathology. If a patient has a pupil abnormality, these three examinations must be performed.

Given how rapidly and easily it can be done, have a low threshold for testing it if you think it might be relevant.

Technique for visual field



[Video - Technique for visual field](#)

1. Begin by explaining what you are going to do. Telling the patient that you are testing their 'peripheral vision' can make it easier for the patient to follow your instructions.
2. Ask the patient to remove their glasses so that the rims do not interfere with the assessment.
3. Sit opposite the patient with your eyes at the same height, about 50cm away from their face.
4. Place a hand over one of your eyes and ask the patient to mirror you, e.g. if you cover your left eye, they cover their right eye.
5. Ask the patient to keep their eye covered, to look directly at your eye with their uncovered eye, and not to look away.
6. Clench the fist of your free hand and hold it in a reasonably peripheral position in one quadrant of your peripheral vision.

7. Ask the patient how many fingers they see and hold up a random number. Look at the patient's eye to ensure that they do not look at your hand.
8. Test in all four quadrants in the same manner and repeat the process on the other side.
9. Test for a scotoma by slowly moving your finger from an area where the patient cannot see to where they can. Repeat until you have mapped the scotoma to your satisfaction.

Notes

Visual field testing to confrontation is unlikely to allow you to detect subtle or small visual field defects but larger defects can be detected.

As you are sitting opposite the patient, your visual field is a reasonable approximation of theirs. It is important to hold your hands in the same coronal plane in each position and equidistant from you and the patient. Neglecting to do this distorts the field that you are assessing.

You can use the hand that was covering your eye, provided you keep that eye closed and remember the position of that monocular visual field with your hand in place. This makes the examination more fluid. Alternatively, you can switch hands.

You can hold up several finger combinations in each quadrant to ensure that the patient can see them.

It is not uncommon for patients to inadvertently look at your hand when they realise your fingers are moving. The most important thing is to recognise when this happens, remind the patient to look at your eye instead and repeat the step with a different number of fingers.

A patient's visual acuity must be at least counting fingers to allow you to test their field to confrontation.

Technique for eye movements

Eye movement examination must be performed in any patient with diplopia (double vision), pupil or eyelid abnormalities.

Eye movement examination technique requires the following:

1. Explain what you are going to do by asking the patient to keep their head still and follow your finger with their eyes.
2. Hold your index finger up in front of the patient, then trace an 'H' pattern in a coronal plane in front of them.
3. Ask the patient to tell you if they have double vision, (e.g. 'see two fingers') in any position of the 'H'.
4. Following this, assess each eye separately by asking the patient to cover one eye and testing the movements of the other side.
5. Switch over so that both eyes are assessed in this way. If the patient is experiencing binocular diplopia, they will not experience diplopia when one eye is covered.

Notes

When testing eye movements, it may help to gently place a finger on the patient's chin or forehead to remind them not to follow with their head.

If a patient has an eye movement disorder you must check their pupils, eyelid and visual field.

In a sixth (6th) cranial nerve palsy, the patient may not be able to abduct their eye. In a third (3rd) cranial nerve palsy, the patient may not be able to elevate, depress or adduct the eye, and you may notice associated pupil and eyelid changes.

In an orbital wall fracture, the patient may not be able to move the eye in the opposite direction, especially if there is associated entrapment of the extraocular muscles (e.g. inability to elevate the eye in an orbital floor fracture).

Eyelid examination

Eyelid examination must be performed in any patient with diplopia (double vision), pupil abnormalities or eye movement disorder and requires the following:

- Observe for ptosis (drooping of the upper eyelid over the eye, which may be unilateral or bilateral). Compare the position of the upper eyelid on one side with the other. This can be done by simply judging the relation of the upper eyelid to the top of the pupil or more accurately by measuring the vertical height of the palpebral aperture with a ruler.
- Ask the patient to close their eyes. Determine whether there is any weakness in this action by first observing and then gently trying to part the eyelids.

Notes

Opening the eye relies upon the third (oculomotor) cranial nerve and the sympathetic fibres. Therefore, a lesion of the oculomotor nerve causes ptosis, and if severe enough, inability to open the eye. A lesion of the sympathetic fibres causes Horner syndrome and less ptosis.

Other causes of ptosis include trauma, swelling of the upper eyelid or age-related degeneration of eyelid tissue.

Closing the eye relies upon the seventh (7th or facial) cranial nerve. Lesion of the facial nerve can result in an inability to close the eye, in addition to drooping of the lower eyelid and the corner of the mouth. Testing for eyelid closure in this manner is the same manoeuvre used in checking facial nerve function.



Inability to close the eye is called lagophthalmos and, if severe, can lead rapidly (within hours) to corneal exposure, irreversible scarring and blindness.

Eyelid eversion

Eyelids must be everted to exclude a subtarsal foreign body.

Technique

1. Ask the patient to look down.
2. Gently pull the upper eyelid down and away from the globe using the eyelashes.
3. Place a cotton bud at the midpoint on top of the eyelid, then bend the eyelid up over the cotton bud.
4. Slide the cotton bud out and either replace it on the lid margin to hold the lid in position or use your finger to do so.



[Video - Eyelid eversion](#)

Notes

It is most efficient to evert an eyelid at the slit lamp, as your view of any potential subtarsal foreign bodies will be better. These may be gently removed with a moist cotton bud.

Patients are often quite averse to having their eyelids everted. Explain what you are going to do, and that while it may feel unusual, it should not be uncomfortable.

It may be easier to grip the edge of the eyelid and eyelashes if you wear a glove.

Figure 12. Everting eyelid.

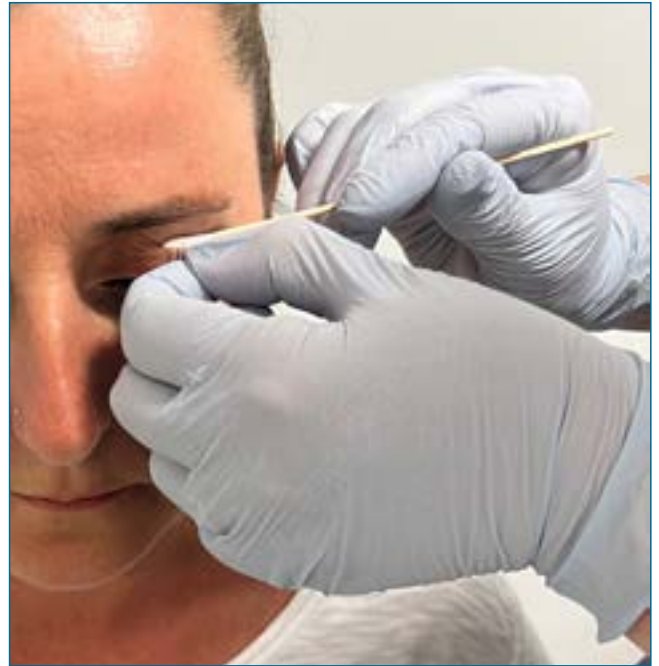
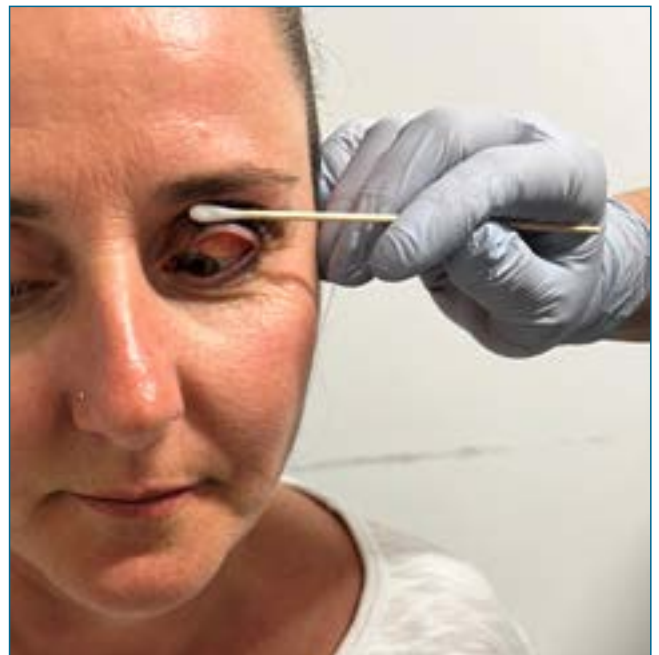


Figure 13. Everting eyelid.



Special eye examinations

Direct ophthalmoscope

It is not necessary to perform a detailed examination with a direct ophthalmoscope for an ED ophthalmology assessment, although it is very helpful if you use it to determine whether the patient has a red reflex or not. Examination with a direct ophthalmoscope does not take priority over the simple assessment of visual acuity, pupils and general inspection.

Do not dilate a patient's pupils until you have spoken with an ophthalmologist as it means that an RAPD cannot be assessed and the patient cannot have pupil observations for several hours.

Technique



[Video - Direct ophthalmoscope examination](#)

1. Watch the video of direct ophthalmoscope examination.
2. Darken the room and ask the patient to look at a target behind you on the wall.
3. Adjust the dioptric correction to zero. Turn the ophthalmoscope light on.
4. Use the same eye as the one you are examining on the patient, i.e. your right eye for the patient's right eye.
5. Standing back from the patient, look through the viewing aperture and shine the light into the patient's pupil. You should see a red reflection ('red reflex').
6. If necessary, adjust the dioptric correction to improve the clarity of the image.
7. To examine the retina, move in closer, keeping the light focused on the red reflex. You must get very close to the patient (within 5cm).

8. When you are close enough you will see some retinal detail, usually a retinal blood vessel. Follow this vessel until you can see the optic disc.

Notes

The direct ophthalmoscope provides a highly magnified, narrow angle view of the fundus. It cannot reliably be used to examine the retina in sufficient detail to exclude pathology. For this reason, patients with suspected posterior segment pathology such as optic disc swelling or retinal tears need to be examined by an ophthalmologist.

Other tools may be available in your ED also, including a pan ophthalmoscope or a non-mydratic fundus camera. Acquiring one of these is highly recommended.

Loss of the red reflex occurs in several conditions (such as retinoblastoma, cataract, vitreous haemorrhage or retinal detachment) and this information can assist greatly with triaging ophthalmic referrals.

It is much easier to examine the retina if the patient's pupil is pharmacologically dilated. However, pupil dilation prevents subsequent assessment for an RAPD, can rarely precipitate acute angle closure in some patients and obscures neurological observations in patients with a head injury. For these reasons, pupil dilation should only be undertaken after discussion with an ophthalmologist (and, in some cases, a neurosurgeon).

Checking intraocular pressure

Although not available in every ED, several handheld devices can be used to measure intraocular pressure.

Never check intraocular pressure if you suspect that a globe may be ruptured.

Applanation tonometers (e.g. Tono-pen)



[Video - Tono-pen technique](#)

1. Explain what you are going to do to the patient. Position the patient upright, looking in a horizontal direction.
2. Administer topical anaesthetic (tetracaine or plain lignocaine).
3. Place a disposable rubber shield over the tonometer probe. Use a different shield for each patient.
4. Turn the tonometer on using the button on the top of the device. Wait for it to beep and for the display to come on.
5. Holding the tonometer horizontally, gently tap the probe against the centre of the cornea several times. You may need to gently hold the patient's eyelids open to achieve this.
6. The tonometer will make ten recordings in quick succession and then beep loudly, displaying the average intraocular pressure on the screen.

Notes

Patients can be quite anxious about having their pressures checked, as many have unpleasant recollections of the 'puff' tonometers that are commonly used by optometrists. You can reassure the patient that this is a different technique and that while it may feel unusual, it will not be uncomfortable (apart from the topical anaesthetic).

If holding the patient's eyelids with your fingers, make sure you are not pressing on the globe itself as this will cause an inaccurately high pressure reading. Restrain the eyelids by tethering them to the bony orbital margins.

Always store the tonometer with a cardboard sleeve over the probe, as this part of the device can be very easily damaged.

As with any test, it is possible to get erroneous measurements. If you doubt the reading, repeat the examination.

Troubleshooting tips are to ensure the sleeve is taut across the tip of the device, and that measurements are taken from the central cornea, holding the tonometer in a horizontal position. If you are having difficulty getting ten readings (which should be very rapid), make sure that the tonometer is in contact with the cornea and make very small to-and-fro movements with your hand.

Rebound tonometer (e.g. iCare)



[Video - iCare tonometer technique](#)

1. Tell the patient what you are going to do.
2. Turn the device on. It will prompt you to insert a small, disposable, round-ended pin-like probe. Once inserted, the probe will shudder back-and-forth for a moment as the device confirms its position.
3. Hold the device vertically just in front of the eye. The probe should be horizontal, only a few millimetres away from the eye and pointing at the central cornea.
4. Press the button. The probe will gently rebound off the cornea and then return to position, usually quicker than the patient can blink.
5. Press four more times. The machine will collect five readings and then display the intraocular pressure.

Notes

Explain to the patient that this device is different to the puff tonometry they may have experienced before and that this will not cause any discomfort.

Unlike applanation tonometers, you do not need topical anaesthetic to check the intraocular pressure with a rebound tonometer.

The patient may feel the contact with their cornea, but the sensation is remarkably light and, in some cases is only barely noticed.

Because rebound tonometers are so fast, you often do not need to hold the patient's eyelids. However, the rapid succession of beeps and barely appreciated sensations on the cornea can be bewildering. It often helps to pick your moment and time each measurement between blinks. Speaking calmly to the patient and reassuring them is very important.

A rebound tonometer may be superior for checking intraocular pressure in children because it is so rapid and does not need topical anaesthetic or pressure on the eyelids.

Some rebound tonometers can be held at orientations other than vertical, making them more useful for recumbent and bed-bound patients.

Slit lamp

A slit lamp is a binocular microscope with an adjustable, confocal light source that enables the ophthalmologist to examine the eye in detail, from the eyelids to the retina. Although a slit lamp examination is often not wholly necessary for the basic assessment of an ophthalmology patient, it is certainly preferable and remains vital for such conditions as corneal foreign bodies and corneal epithelial defects.

Technique (e.g. Haag-Streit slit lamps)



[Video - How to use a slit lamp in 5 minutes](#)



[Video - Slit lamp basic examination](#)

1. Ensure that both you and the patient are sitting on height-adjustable chairs. Bring both chairs close to the slit lamp.
2. Adjust the table height so that the patient can place their chin on the chin rest and their forehead can touch the headrest.
3. Adjust the height of the chin rest so that the patient's lateral canthus is aligned with the black grooved line on the vertical support.
4. Adjust the eyepieces so that they are both at 'zero'. If you have a refractive error, it is best to wear your own spectacles. While it is possible to adjust the optics of the slit lamp to compensate, this can create unnecessary confusion.
5. Turn the filter selection switch to the left-most (or second from left-most) position. This is the brightest setting and will allow you to see more of the eye. While it is bright, the patient's perception of brightness comes mostly from the width of the beam.
6. Adjust the aperture height knob to create a maximally tall beam (8mm) and the aperture width knob to create a very narrow beam (<0.5mm). This gives the best viewing characteristics. A beam that is too wide will make it harder for you to appreciate depth and be uncomfortable for the patient.
7. Turn the illumination arm to the same side as the eye that you are examining and angle it between 30° and 60° from the midline. Ask the patient to look at your opposite ear with their other eye. Switch the arrangement when you switch eyes.
8. Turn the slit lamp on and adjust the characteristics of the light beam if needed.
9. Begin by coarse-focusing. Do not look through the microscope initially, but instead look beside it at the light shining on the patient's face. Move the whole slit lamp base to bring the light into sharp focus on the patient's eye. You can then look through the microscope.
10. Adjust the width of the eyepieces as you would on a pair of binoculars.
11. Fine-focus moving the joystick backwards and forwards. There is nothing else you need to do to focus. Experiment by moving backwards and forwards and observing the effect it has on what you can see. You can move the beam up and down by turning the joystick.
12. When focused on the eye, examine the periocular skin, lids, eyelashes, cornea, iris and lens in an anteroposterior systematic fashion. Note the location, size and apparent composition of any foreign bodies.

13. To search for a corneal epithelial defect, administer a drop of fluorescein and examine with the cobalt blue light. This is obtained by turning the height aperture knob beyond 8mm until a stop with a blue dot appears. The beam will turn blue. Widen your beam to the maximum, as you will usually want to scan the ocular surface for fluorescein staining.
14. When finished, turn the slit lamp off and ask the patient to sit back. Do not leave the patient stranded or trapped behind the slit lamp or with their feet elevated off the ground.

Notes

Patients sometimes lean back during the examination, pulling their forehead away from the headrest and causing the eye to go out of focus. Check the patient's position periodically and remind them to come forward again if they have drifted away. Checking head position is essential during foreign body removal procedures.

Ergonomics are important. Adjust the height of your chairs and that of the table to ensure comfort. Apart from causing injury, if the patient is uncomfortable, they are more likely to drift away, and if you are uncomfortable, you are less likely to examine them thoroughly.

The cobalt blue light is obtained by turning the height aperture knob one click beyond 8mm. The green filter (on the filter selection switch) is commonly mistaken for the cobalt blue light but it has different optical characteristics. If you are looking for an epithelial defect with a green light, then stop, turn the filter selection switch back to the left and adjust the height knob until it stops at the blue light.

Use the terms 'corneal epithelial defect' or 'punctate epithelial erosions' when describing what you see with fluorescein and the cobalt blue light. 'Diffuse fluorescein uptake' is not a useful descriptive term, and usually means that the slit lamp was out of focus, that the green

light was used instead of the blue or that the examiner put too much fluorescein into the eye and did not wait for it to disperse.

The technique for looking for cells is to darken the room, adjust the height and width apertures to produce a 1mm x 1mm beam, and direct it from 45° across the patient's pupil while focusing on the middle of the anterior chamber. Increase the magnification by switching the lever beneath the eyepieces. Cells will be illuminated against the dark backdrop of the pupil as they traverse the light beam, like dust particles in a sunbeam. While this is a good thing to test for, it is not considered a standard part of the ED assessment.



[Video - Slit lamp examination for cells and flare](#)

As mentioned above, you can adjust the magnification by switching the lever beneath the eyepieces. This can be useful in certain situations, but in general, keep the slit lamp on the lower magnification. This makes it easier to focus and the more zoomed-out view will give you a better appreciation of normal anatomy and pathology.

Turn the slit lamp off when you are finished examining and clean its surfaces between patients.

Troubleshooting

If there is no light when you turn the slit lamp on, check that:

- it is plugged in and turned on at the power point
- the LED light next to the ON switch is illuminated
- the width and height apertures are open.

Notes

If the width aperture is closed no light will appear. This is a common reason for no light to appear. Simply widen the beam to fix this. Similarly, if the height aperture or one of the filters is turned halfway between stops, light may not appear. Turn all the way to a stop to fix this.

Does the bulb need to be replaced?

If these simple points are addressed and there is still no light, this may be the case. Emergency departments usually have spare bulbs, but only someone who has experience replacing a bulb should do so. Ensure that the slit lamp is turned off and unplugged before proceeding. If the bulb housing is screwed down too tightly, or the bulb is not aligned properly in the socket, it may not work until these issues have been corrected.

If the view is blurry, try:

- wearing your own glasses
- ensuring the eyepieces are fully pushed in and dialled to 'zero'
- going through the same process of coarse- and then fine-focus.

The eyepieces (or oculars) can be adjusted to account for your refractive error or induced instrument myopia. However, it is simpler to wear your own spectacles and keep the oculars on 'zero' (align the little mark opposite '0'). The eyepieces can also be removed (for cleaning) and occasionally you will encounter slit lamps in which the oculars have been inadvertently left partially out. Push them in to make your view clearer.

If you are seeing clearly but not with both eyes, try:

- adjusting the interpupillary distance by altering the width between the eyepieces just like a pair of binoculars
- moving the light column slightly to one side or the other (sometimes the light column can obstruct the view through one eyepiece).

Eye referrals and discharge advice

Trauma communication checklist

Follow ISBAR:

- ☒ What is the mechanism of trauma?
- ☒ Are you concerned about an open globe injury?
- ☒ Is there a history of previous eye surgery or injury?
- ☒ What is the visual acuity (including with pinhole if not 6/6)?
- ☒ Is there an RAPD?
- ☒ What are the findings on slit lamp examination with fluorescein?
- ☒ Does the patient have other injuries?
- ☒ What treatment has been commenced?

Acute visual disturbance communication checklist

Consider the following in the presenting patient:

- ☒ Presenting complaint: timing, worsening/improving, monocular/binocular
- ☒ Past ocular/medical history
- ☒ Visual acuity
- ☒ Visual fields (by confrontation)
- ☒ Pupil examination (anisocoria and presence of an RAPD)
- ☒ Red reflex
- ☒ Dilated retinal examination

Red eye or eyelid communication checklist

Consider the following in the presenting patient:

- ☒ What was the onset and duration of symptoms?
- ☒ Is the eye painful or not painful?
- ☒ What is the distribution of redness? Is it localised or diffuse? Does it involve the tarsal conjunctiva?
- ☒ Is the condition purely unilateral or are there contralateral symptoms?
- ☒ What is the best (pinhole) visual acuity of each eye?
- ☒ Are the eyelids involved? Are they red or swollen?
- ☒ Is the cornea normal? Are cloudiness, opacities or fluorescein staining visible?
- ☒ Is the anterior chamber normal? Is it deep? Presence of anterior chamber cells, blood or hypopyon?
- ☒ Is the iris normal? Round, equal, reactive pupils? Are the normal iris details visible?
- ☒ Are the red reflexes equal?

Visual requirements for driving

Be aware of driving requirements when assessing a patient with an ophthalmic complaint. Visual requirements differ depending on whether someone is a private or commercial driver. A commercial driver is anyone who drives during their occupation other than to and from work (such as bus, truck and taxi drivers, and most couriers) and there are more stringent licensing requirements than for private vehicle driving.

Private vehicle licence: visual acuity of 6/12 or better with both eyes open or in the better eye.

Commercial vehicle licence: visual acuity of 6/9 or better in the better eye AND 6/18 or better in the poorer eye.

For drivers in NSW, further information is available from [Transport for NSW](#).

A person with only one eye (monocular) cannot hold an unconditional private or commercial driver's licence. A conditional licence may be considered by the driver licensing authority subject to 2-yearly review, considering the nature of the driving task and information provided by the treating optometrist or ophthalmologist. Specific visual standards must be met that differ for private versus commercial drivers.

A period of adaptation is required (usually 3 months) after someone is rendered monocular before they can resume driving. This is because it takes time to compensate for the loss of binocularity and peripheral field and become familiar with the monocular cues that can provide a simulacrum of binocular viewing.

Patients with symptomatic diplopia (double vision) are not permitted to drive. While wearing a patch (or occluder) over one eye can abolish binocular diplopia, it also renders the patient monocular and hence the 3-month adaptation period applies.

A visual field with both eyes open of 110° horizontally and 20° vertically (at least 10° above and below the horizontal midline) without any significant field loss within the central 20° is required for private driving licences. A commercial driver is not fit to hold an unconditional licence if they have a visual field defect. A conditional licence may be considered if the binocular visual field is static, has an extent of at least 140° within 10° above and below the horizontal midline and no significant field loss is likely to impede driving performance. A homonymous quadrantanopia or hemianopia is considered inadequate peripheral vision. Formal visual field assessment (perimetry) is done by an optometrist or ophthalmologist.

If a patient has a visual acuity or field defect that violates these requirements, it is your responsibility to inform the patient that they cannot drive and document this discussion. In some Australian states, it is also mandatory for the doctor to contact the licensing authority to inform them that the patient's licence must be suspended.

The Austroads national driver medical standards [Assessing Fitness to Drive](#) set out the considerations and medical criteria for safe driving.

Prevention of visual impairment

The main causes of visual impairment in Australia are cataracts, macular degeneration and glaucoma, with the common main risk factor of age. With an ageing population, the prevalence of visual impairment is expected to rise.

Diabetic retinopathy

Diabetic retinopathy is the main cause of blindness among the Australian working population. It is well established that the microvascular complications of diabetes, such as retinopathy, can be prevented by tight glycaemic control. Health professionals have the important responsibility of educating patients, including promoting lifestyle changes such as smoking cessation, exercising regularly and maintaining a healthy, well-balanced diet. These not only improve glycaemic control but also lower blood pressure and reduce the risk of developing other eye conditions such as macular degeneration and glaucoma.

Children

Children under the age of 8 are a unique group where any significant ocular pathology must be addressed during this 'critical period' of visual development. Prolonged visual deprivation, strabismus or refractive errors lead to amblyopia, which means that the affected eye will have poorer acuity even if the visual pathway is later optimised. Therefore, the importance of screening children on more than one occasion during this 'critical period' cannot be overemphasised.

Ocular trauma is a major preventable cause of visual impairment, with several studies suggesting that 90% of cases are avoidable. For reasons that remain unclear, children are overrepresented in this group. Education, such as the [EYEPLAYSAFE online modules](#), aims to increase awareness of potential hazards in school, at home and in outdoor environments that may lead to ocular injury.

Work injuries

In the adult population, those who work with any form of metal, particularly using powered hand tools, are at increased risk of penetrating eye injuries. Globe rupture tends to occur more frequently in the older population, with the combination of falls and a weakened globe, (e.g. from previous cataract surgery) placing them at particular risk.

The mandatory use of safety eyewear in the workplace that complies with Australian Standards and recommends the use of protection at home when performing do-it-yourself activities should be reinforced. Patients who present with a superficial foreign body should be counselled about these risks. Furthermore, patients who have intraocular surgery should be counselled about the risk of globe rupture in the future, even with only minor trauma, which usually has a very poor visual outcome.

These statistics highlight the importance of implementing prevention strategies to reduce the burden of disease caused by visual impairment within Australia, and primary care health professionals are perhaps in the best position to promote these.

NSW public specialist outpatient services

This information is designed as a guide only and does not replace clinician judgment.

Use the link below for statewide referral criteria (SRC) for ophthalmology.

<https://www.health.nsw.gov.au/outpatients/referrals>

Eye trauma



Eye trauma

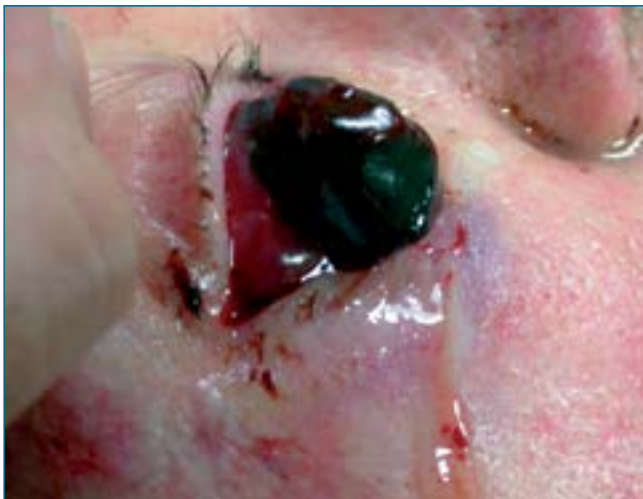Blunt ocular trauma



Consider the following for blunt eye trauma:

- Difficulty opening eyelids and a very tense orbit suggest retrobulbar haemorrhage.
- Exclude serious head injury depending on the mechanism of injury and consider a brain CT.
- Previous eye surgery increases the risk of open globe injury.
- Small projectiles at high velocities increase the likelihood of penetrating trauma.

Figure 14. Ruptured globe with the expulsion of ocular tissues.



History findings

- Mechanism of injury: if applicable, the type of projectile and velocity should be documented
- Flashes and/or floaters: suggest retinal injury
- Double vision: suggests muscle injury or nerve palsy
- Previous eye surgery or injury increases the risk of open globe injury
- Eye protection worn does NOT exclude open globe injury

Examination findings

- Gently open lids: exclude obvious open globe injury or retrobulbar haemorrhage (topical anaesthetic may facilitate this)
- Visual acuity
- Relative afferent pupillary defect (RAPD)
- Red reflex
- Ocular motility (ask the patient about double vision or pain)
- Check heart rate (oculocardiac reflex from muscle entrapment: bradycardia)
- Palpate for orbital rim tenderness (infraorbital nerve involvement is suggested by abnormal sensation over the cheek, upper lip or teeth)
- Orbital retropulsion but DO NOT test if open eye injury is suspected
- Superficial ocular examination with a slit lamp (or some magnification) to assess for corneal/ conjunctival laceration or penetration
- Further ocular examination, including dilated fundus examination, as determined by history and examination findings

Investigations

- CT orbits: look closely at the coronal and axial sections in soft tissue and bony windows for fracture, globe integrity or retrobulbar haemorrhage

Important differentials

- Open globe injury
- Orbit fracture
- Closed globe injury: anterior = hyphaema or lens dislocation
- Closed globe injury: posterior = retinal tear/detachment, vitreous haemorrhage or choroidal rupture

Initial treatment

- Trauma assessment: exclude life-threatening injuries
- Assume an open globe injury until proven otherwise
- Analgesia and antiemesis (vomiting and other Valsalva may cause loss of intraocular contents in an open globe injury)

Eye trauma communication checklist

Follow ISBAR:

- ☒ What is the mechanism of trauma?
- ☒ Are you concerned about an open globe injury?
- ☒ Is there a history of previous eye surgery or injury?
- ☒ What is the visual acuity (including with pinhole if not 6/6)?
- ☒ Is there an RAPD?
- ☒ What are the findings on slit lamp examination with fluorescein?
- ☒ Does the patient have other injuries?
- ☒ What treatment has been commenced?

Specific communication checklist

Consider the following:

- ☒ Why do you think this is an open/closed globe injury?
- ☒ Is the patient ready for operating theatres (considering general health, other injuries and fasting status)?

Chemical burns

Immediate referral to an ophthalmologist.



Ensure the following:

- Once a chemical injury is suspected, you must commence irrigation before further history or examination
- Exclude an open globe injury if the mechanism is suspicious, (e.g. an explosion)

History findings

- Time when the burn occurred
- Nature of chemical, i.e. acid/alkali (note alkalis are more harmful to the eye)
- Any first aid administered and when that was done after the incident

Examination findings

- Consider the following:
- Use topical anaesthesia if necessary
- Trichiasis (inturned eyelashes which may rub on the cornea)
- Visual acuity
- Fluorescein staining (corneal and conjunctival)
- Cornea clear or cloudy (note iris detail visibility)
- Degree of vascular blanching, particularly at the limbus, is proportional to the severity of the chemical burn (see Figure 15, Figure 16 and Figure 19 for comparison)
- Evert eyelids and note any retained particulate matter

Investigations

- Measure pH for both eyes using universal indicator paper in the conjunctival fornix (or a cut-off urine dipstick if unavailable)
- Repeat pH testing after every second litre of fluids

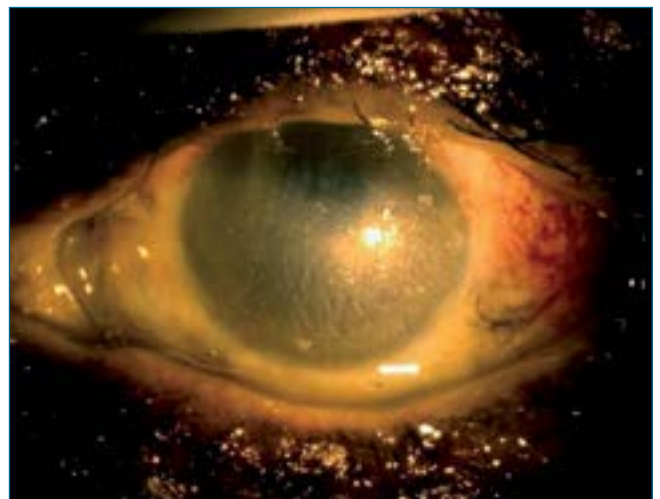
Important differentials

- Retained particulate chemical
- Thermal injury
- Exclude open globe injury, penetrating or mixed mechanism injuries, (e.g. explosions)

Figure 15. Acute alkali chemical injury (mild/moderate).

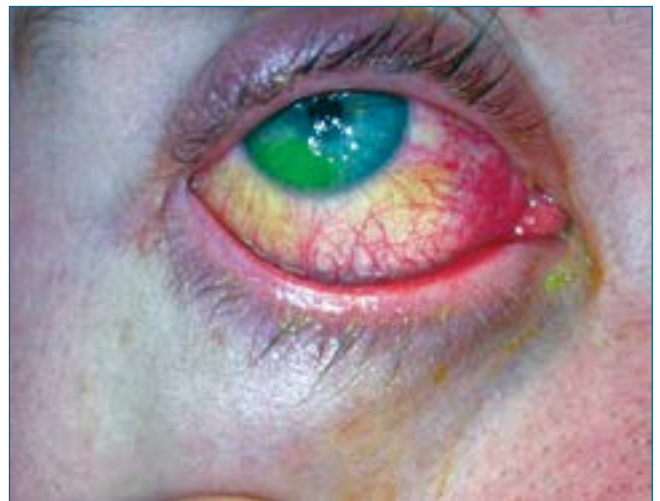

Figure 16. Acute alkali chemical injury (severe).



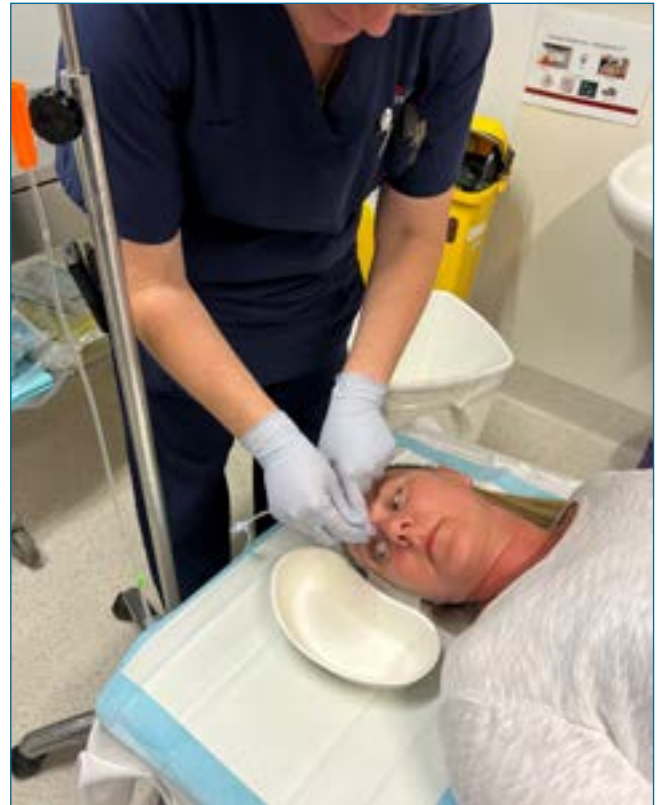Initial treatment

Immediate:

Eye irrigation for chemical burns

1. Administer local anaesthetic drops to the affected eye/eyes.
2. Commence irrigation with 1L of a neutral solution, e.g. Hartmann's, normal saline (0.9%) in an IV giving set on full flow.
3. Evert the eyelid and clear the eye of any debris or foreign body that may be present by sweeping the conjunctival fornices with a moistened cotton bud.
4. Irrigate from 3–5cm above the ocular surface. Ask the patient to look left, right, up and down whilst irrigating.
5. Use nitrous oxide/ketamine if necessary for irrigation.
6. Review the patient's pain level every 10 minutes and instill another drop of local anaesthetic as required.
7. Review after 1L of irrigation administered.
8. Wait 5 minutes after ceasing the irrigation fluid then check the pH in BOTH eyes (acceptable pH range 6.5–8.5). Compare with unaffected eye's pH if unilateral injury.
9. Consult with the senior medical officer or ophthalmologist and recommence irrigation if necessary.
10. Severe burns and alkalis usually require continuous irrigation for at least 30 minutes with 3L of fluid.

Figure 17. Irrigation with the eyelid everted.



Eye trauma communication checklist

Follow ISBAR:

- ☒ What is the mechanism of trauma?
- ☒ Are you concerned about an open globe injury?
- ☒ Is there a history of previous eye surgery or injury?
- ☒ What is the visual acuity (including with pinhole if not 6/6)?
- ☒ Is there an RAPD?
- ☒ What are the findings on slit lamp examination with fluorescein?
- ☒ Does the patient have other injuries?
- ☒ What treatment has been commenced?

Notes

- The emergency treatment of a chemical injury has far greater impact on the final ocular outcome than any other factor. Prompt and thorough irrigation is critical to avoiding a painful, permanently blind eye in these patients.
- Examples of acids include toilet cleaner, car battery fluid and pool cleaner.
- Examples of alkalis include bleach, lime/cement, mortar and plaster, drain cleaner, oven cleaner and ammonia.
- Alkalis saponify ocular tissues and continue to burn deeper into the eye, hence they require more irrigation.
- For medicolegal reasons, it is important to document when and how the injury occurred, whether eye protection was present and whether on-site first aid was given.

Specific communication checklist

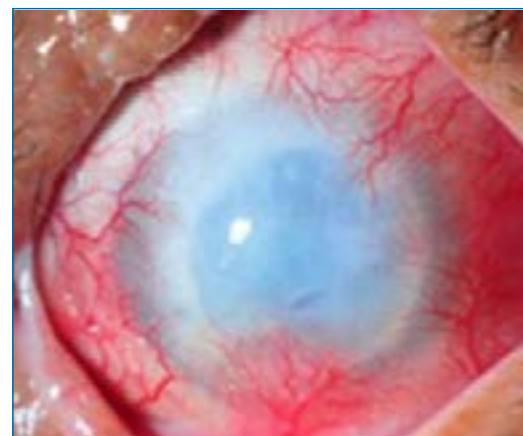
Consider the following:

- ☒ What chemical was involved?
- ☒ What irrigation has already been administered?
- ☒ Have you everted the upper and lower eyelids?
- ☒ What is the pH?

Figure 18. Universal indicator paper.



Figure 19. Typical long-term outcome of a severe chemical ocular injury. While a corneal transplant has been attempted, this has failed and become opacified and vascularised. Limbal stem cell damage by chemical injury results in a very poor long-term visual prognosis.¹



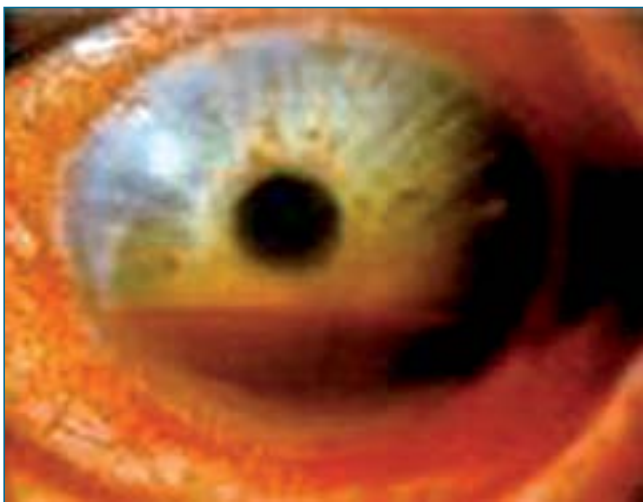Closed globe injury

Urgent referral to an ophthalmologist required <24hrs.



- History of eye surgery (assume the patient has an open globe injury until proven otherwise)
- Reduced visual acuity, not improved by pinhole
- RAPD
- Loss of red reflex
- Photophobia
- Photopsia (flashing lights like a camera flash) or floaters suggesting retinal injury
- Irregular pupil
- Difficulty opening eyelids and a tense orbit suggest retrobulbar haemorrhage

Figure 20. Hyphaema: blood in the anterior chamber.



Important findings

- Hyphaema
- Traumatic mydriasis
- Lens dislocation
- Loss of red reflex with vitreous haemorrhage
- Retinal detachment

History findings

- Mechanism of injury
- Timing of visual loss after injury (immediate/delayed, stable/progressive)
- Quality of visual loss: blurring, floaters, curtain, greying or total blackness, scotoma
- Any previous ocular surgery (this increases the risk of open globe injury)
- Double vision: suggests muscle injury or nerve palsy

Examination findings

- Visual acuity
- Slit lamp examination with fluorescein
- Shallow or deep anterior chamber and hyphaema
- Red reflex
- Check pupils for an RAPD and anisocoria
- Visual fields by confrontation
- Extraocular movement
- Fundus examination

Investigations

- Check intraocular pressure (only if open globe injury has first been excluded)

Important differentials

- Open globe injury
- Head injury or fracture
- Orbital fracture or retrobulbar haemorrhage
- Closed globe injury: anterior = corneal abrasion, hyphaema and lens dislocation
- Closed globe injury: posterior = retinal detachment, vitreous haemorrhage and choroidal rupture

Initial treatment

- Rest at 45°
- Shield the eye (do not pad)

Eye trauma communication checklist

Follow ISBAR:

- ☒ What is the mechanism of trauma?
- ☒ Are you concerned about an open globe injury?
- ☒ Is there a history of previous eye surgery or injury?
- ☒ What is the visual acuity (including with pinhole if not 6/6)?
- ☒ Is there an RAPD?
- ☒ What are the findings on slit lamp examination with fluorescein?
- ☒ Does the patient have other injuries?
- ☒ What treatment has been commenced?

Notes

Blunt trauma to the eye may result in considerable damage to the intraocular contents. Fracture of the orbital wall may occur due to the transfer of mechanical energy to the relatively thin orbital bone.

Slit lamp examination must include fluorescein to look for leaking aqueous in open globe injury.

Is the anterior chamber shallow or deep?
Angle a tall and thin light beam at 45° to assess anterior chamber depth.

Consider globe ultrasound if loss of red reflex or poor visual acuity (only if open globe injury has been excluded first).

Flash burns

History findings

- Mechanism (electric arc welding or UV light, e.g. fish tank, sun lamp or skiing without eye protection)
- Symptoms typically appear within several hours
- Symptoms are usually intense pain, red eye, photophobia, blepharospasm and tearing

Examination findings

Consider the following:

- Use topical anaesthesia in the examination (it will usually relieve pain completely) or small amounts of analgesia, e.g. IV opioid or methoxyflurane.
- Visual acuity: often mildly decreased (repeat +/- pinhole after local anaesthesia).
- Slit lamp: conjunctival injection, widespread superficial punctate epithelial defects staining with fluorescein (often bilateral).

Investigations

- Not required

Important differentials

- Chemical injury
- Corneal foreign body

Initial treatment

- Topical antibiotic drops of preservative-free artificial tears q1–2hr prn (ointment may be soothing especially overnight)
- Cycloplegic, (e.g. cyclopentolate 1% bd) for comfort for 2 days
- Oral analgesia as required (stronger than paracetamol)
- Inform patients to re-present if symptoms have not improved appreciably after 24 hours

Eye trauma communication checklist

Follow ISBAR:

- ☒ What is the mechanism of trauma?
- ☒ Are you concerned about an open globe injury?
- ☒ Is there a history of previous eye surgery or injury?
- ☒ What is the visual acuity (including with pinhole if not 6/6)?
- ☒ Is there an RAPD?
- ☒ What are the findings on slit lamp examination with fluorescein?
- ☒ Does the patient have other injuries?
- ☒ What treatment has been commenced?

Lid laceration

Immediate referral to an ophthalmologist.



An eyelid laceration is a potential penetrating eye injury until proven otherwise.

Questions to ask the patient:

- Which eye is injured?
- How did it happen? Was there any possibility of penetration into the eye/orbit/brain?
- When did it happen?
- What are the symptoms, (e.g. blurred vision, watery eye or red eye)?

Figure 21. Exploration of an extensive lid laceration.

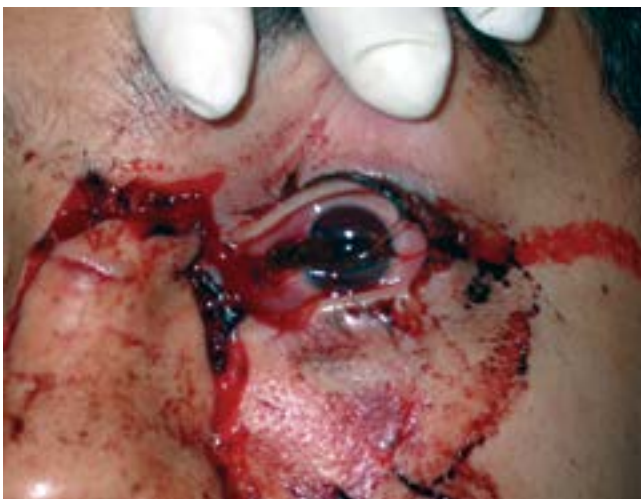
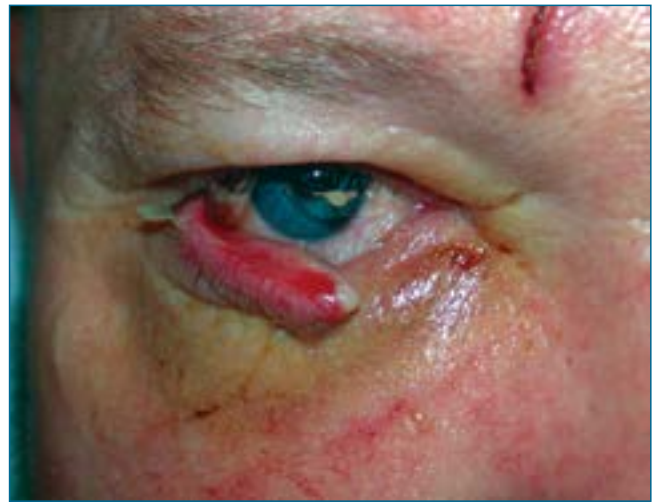
Figure 22. Torn eyelid with avulsed lower lacrimal canaliculus from a dog bite injury.



Examination findings

- Wound examination (size and depth, tissues visualised, e.g. skin, muscle or septum)
- Visual acuity
- Superficial ocular examination with a slit lamp (or some magnification) and fluorescein to assess for any corneal/conjunctival laceration or penetration
- Further ocular examination including the extent of lid closure, eye movements and dilated fundus examination as determined by history and examination findings
- Always consider the possibility of a retained foreign body

Investigations

- Orbital CT if suspicious for foreign bodies or orbital fracture (plain X-ray has poor sensitivity)

Important differentials

- An eyelid laceration is a potential penetrating eye injury until proven otherwise.
- Note the extension of injury to surrounding tissues (globe, orbit, lacrimal drainage apparatus, paranasal sinuses and brain).

Initial treatment

- Any laceration other than superficial skin will need an ophthalmic referral
- Involvement of the medial eyelid (where the lacrimal drainage apparatus resides) or of the eyelid margin requires ophthalmic referral within 48 hours for repair
- Check for tetanus immunisation status

Treatment if superficial laceration does not involve the lid margin or lacrimal drainage apparatus:

1. Clean the area and surrounding skin with antiseptic such as Betadine.
2. Subcutaneous anaesthetic with a vasoconstrictor (2% lignocaine with adrenaline).
3. Irrigate and debride the wound thoroughly with saline.
4. Remove foreign bodies if applicable.
5. Suture with a 6/0 non-absorbable suture.
6. Remove sutures within 5 days.

Eye trauma communication checklist

Follow ISBAR:

- ☒ What is the mechanism of trauma?
- ☒ Are you concerned about an open globe injury?
- ☒ Is there a history of previous eye surgery or injury?
- ☒ What is the visual acuity (including with pinhole if not 6/6)?
- ☒ Is there an RAPD?
- ☒ What are the findings on slit lamp examination with fluorescein?
- ☒ Does the patient have other injuries?
- ☒ What treatment has been commenced?

Specific communication checklist

Consider the following:

- ☒ Where is the laceration?
- ☒ Is it full thickness (involving the lid margin) or medial to the puncta?

Notes

Eyelid lacerations can cause visual loss from corneal scarring and permanent discomfort from poorly functioning eyelids, or recurrent infection and watering if there is damage to the lacrimal drainage system.

Non-accidental injury (NAI)

Seek immediate referral to the ophthalmologist on the same day.



Referral urgency: immediate to the child protection unit.

History findings

- The stated mechanism of injury is inconsistent with examination findings
- Changing history of injury
- Recurrent or delayed hospital presentations

Figure 23. Fundus photographs of retinal haemorrhages in neonates with a history of birth asphyxia and amniotic fluid aspiration.²

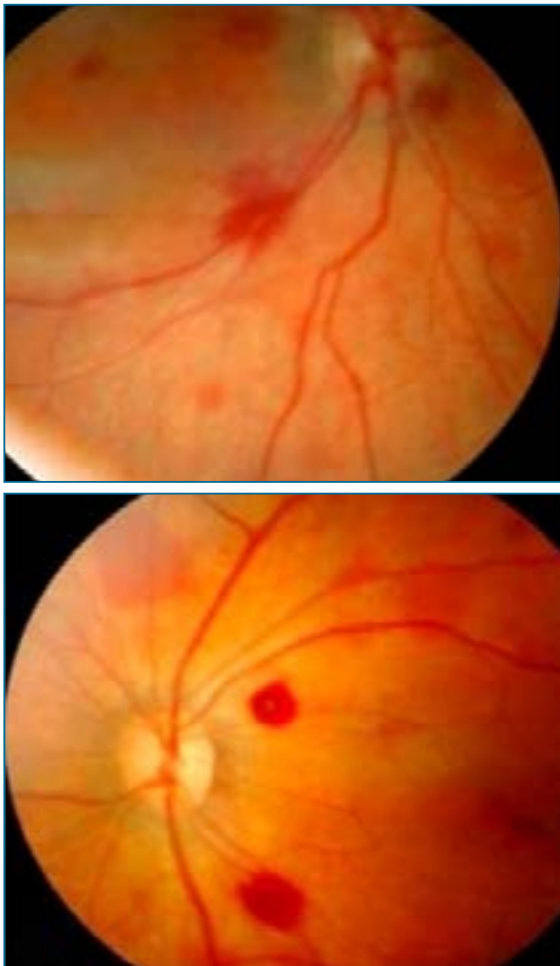
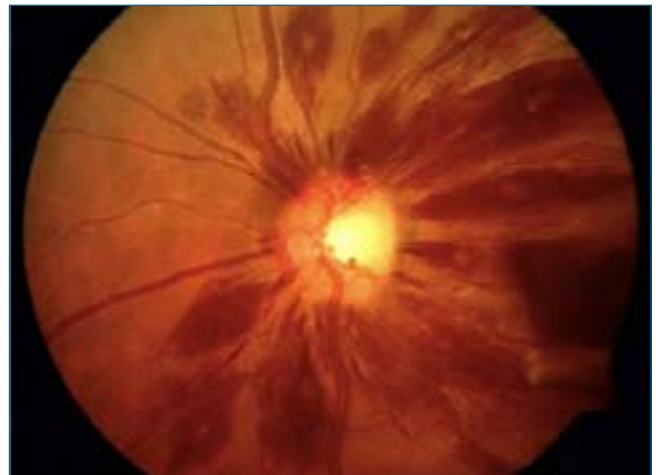


Figure 24. Peripapillary white-centred retinal haemorrhages.³



Initial treatment

In a suspected NAI in a child, ensure:

- urgent referral to an appropriate paediatric team and child protection unit for multi-disciplinary assessment and management
- an ophthalmologist review for fundoscopic signs of trauma is required as part of the work-up.

Open globe injury (penetrating eye injury)

Seek an immediate referral to an ophthalmologist.

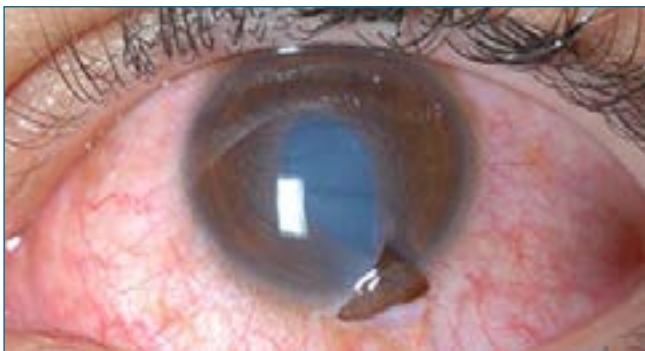History findings

- Mechanism (small objects moving fast are more likely to cause a penetrating eye injury)
- Timing of visual disturbance after the injury

Examination findings

- Examination may only need to be cursory if the trauma is obvious
- Visual acuity and RAPD
- Direct ophthalmoscopy (loss of red reflex may suggest retinal trauma or detachment)
- Slit lamp with fluorescein (looking for distorted anterior chamber structures, corneal/scleral breaks and Seidel test)

Figure 25. Penetrating eye injury, with a small amount of iris tissue extruding through the corneal wound. Also note the teardrop-shaped pupil and the lens opacification.



Photograph courtesy of Lawrence B. Stack, MD, Professor of Emergency Medicine and Paediatrics, Vanderbilt University Medical Center, Nashville, Tennessee, USA.

Figure 26. Seidel test positive: the observation of the ocular surface stained with 2% fluorescein under diffuse, bright cobalt blue light reveals a waterfall-like effect as clear aqueous exudes through a penetrating corneal wound and displaces the fluorescein-stained tear film.⁴

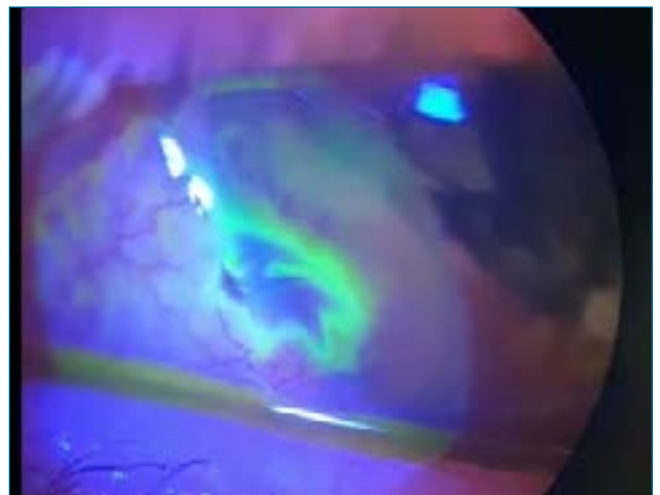
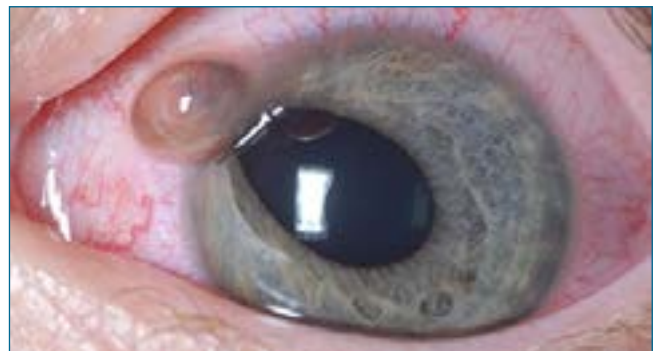

Figure 27. Penetrating eye injury, with iris tissue extruding through the corneal wound. Note the tear-drop pupil. The eye is otherwise uninflamed, with the cornea and lens both clear.



Photograph courtesy of Lawrence B. Stack, MD, Professor of Emergency Medicine and Paediatrics, Vanderbilt University Medical Center, Nashville, Tennessee, USA.

Initial treatment

- Shield the eye (do not use a pad) to avoid inadvertent pressure on the globe
- Antiemetic to avoid expulsion of ocular contents
- Analgesia if required
- IV antibiotics (broad spectrum)
- Tetanus prophylaxis
- Keep nil by mouth, strict bedrest and prepare for theatre
- No ointment for penetrating eye injury
- Consider a fine-cut orbital CT scan to look for a foreign body

Eye trauma communication checklist

Follow ISBAR:

- ☒ What is the mechanism of trauma?
- ☒ Are you concerned about an open globe injury?
- ☒ Is there a history of previous eye surgery or injury?
- ☒ What is the visual acuity (including with pinhole if not 6/6)?
- ☒ Is there an RAPD?
- ☒ What are the findings on slit lamp examination with fluorescein?
- ☒ Does the patient have other injuries?
- ☒ What treatment has been commenced?

Specific communication checklist

Consider the following:

- ☒ What was the likely cause?
- ☒ Is there a positive Seidel test?
- ☒ Is there a retained foreign body/bodies clinically or on CT?
- ☒ When has the patient fasted from?

Notes

- The pupil may point towards a corneal perforation or be irregular.
- There may be an iris defect or early lens opacification visible when examining the red reflex carefully.
- Fluorescein will light up in a waterfall-like appearance from a leaking corneal wound (Seidel sign). An entry wound may not be obvious and may be hidden by conjunctival tissue or subconjunctival haemorrhage.
- The anterior chamber may be shallow for anterior injuries or very deep for posterior injuries (compare with the other eye).

Orbital fracture



Immediate referral (phone) if reduced vision, reduced heart rate (or vomiting) on up-gaze, evidence of retrobulbar haemorrhage.

Seek an urgent referral to an ophthalmologist <24hr.

Refer to plastic surgery or maxillofacial surgery for consideration of orbital fracture repair.

- Ocular motility (ask the patient about double vision or pain)
- Check heart rate (oculocardiac reflex)
- Palpate orbital rim tenderness (infraorbital nerve involvement is suggested by abnormal sensation over the cheek, upper lip or teeth)
- Retropulsion if open globe injury has been excluded
- Superficial ocular examination with a slit lamp (or some magnification) to assess for any corneal or conjunctival laceration or penetration
- Intraocular pressure check if open globe injury has been excluded
- Fundus examination (do not dilate until intracranial injury is excluded and visual acuity and RAPD are checked)

Important findings

- Poor visual acuity
- Difficulty opening eyelids (retrobulbar haemorrhage)
- Haemodynamic instability or vasovagal syndrome (entrapment of extraocular muscle, usually inferior rectus)
- Exclude head/intracranial injury

History findings

- Mechanism of trauma, including the possible presence of a foreign body, visual disturbance or any diplopia (double vision)
- Photopsia (light flashes) or floaters (suggestive of retinal injury)
- Any previous eye surgery (this increases the risk of an open globe injury)

Examination findings

- Gently open lids to exclude obvious open globe injury or retrobulbar haemorrhage
- Visual acuity (also test with pinhole if not 6/6)
- RAPD
- Red reflex

Investigations

- CT orbits and fine brain slices: look closely at the coronal and axial sections in soft tissue windows for fracture, globe integrity or retrobulbar haemorrhage

Important differentials

- Retrobulbar haemorrhage
- Open globe injury
- Associated closed globe injury (up to 30% of cases)

Initial treatment

- Analgesia
- No nose blowing (cough/sneeze with open mouth to avoid an increase in sinus pressure, which may displace non-sterile material through fracture and into orbit)
- Broad-spectrum IV antibiotics (see next)

Figure 28. Coronal CT scan: left blow-out fracture.

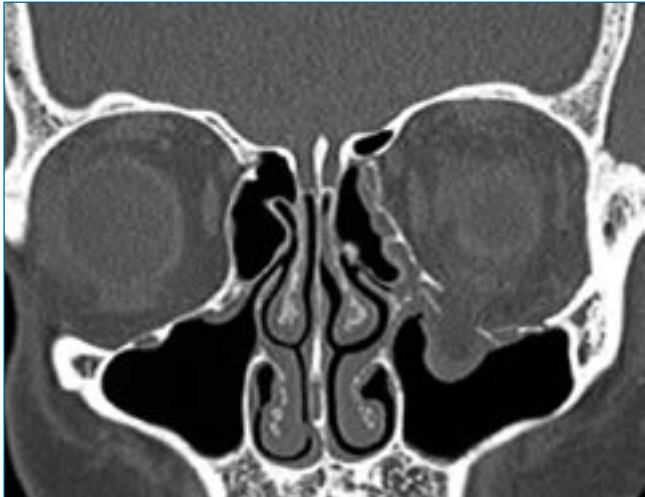

Figure 29. Blow-out fracture: squash ball hit to the eye.



Notes

- Discharge on oral antibiotics, (e.g. Augmentin Duo bd for 7 days) and nasal decongestant spray.
- Gentle ice pack to the orbit for 24–48 hours.
- Surgical repair, if necessary, is usually performed 7 to 14 days after trauma.

Indications for surgical repair of orbital floor fracture:

- Immediate repair: oculocardiac reflex in a young patient with white-eyed blow-out (greenstick) fracture and entrapped muscle.
- Early repair (<2/52): persistent diplopia, enophthalmos and hypoglobus.
- Observation only: minimal diplopia (especially if limited to up-gaze).

Things to consider:

- The force required to cause orbital fracture is often significant enough to also cause closed-eye injuries. Perform an adequate ocular examination, including intraocular pressure.
- The medial wall is thinnest and tends to blow out first but rarely requires surgical intervention.
- The orbital floor is the second most common and can often disturb eye position and movements.
- The lateral wall and roof are more robust and tend to fracture only in higher-force injuries.

Retrobulbar haemorrhage (orbital compartment syndrome)

Seek an immediate referral to an ophthalmologist.

Consider the following:



- Are there systemic or intracranial injuries?
- Is the patient on anticoagulants? If so, this increases the likely need for intervention.

Examination findings

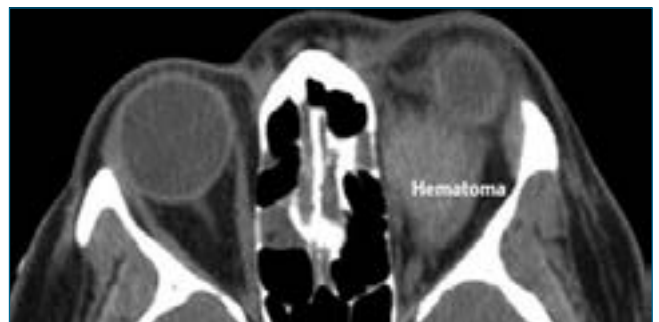- Tense orbit: difficulty opening eyelids with your fingers
- Haemorrhage confined to the orbital rim
- Chemosis (conjunctival swelling)
- Raised intraocular pressure and resistance to repulsion: press your index finger against each globe through the closed lids
- Limited ocular motility, i.e. pain or diplopia (double vision)
- Reduced vision: if severely reduced vision, consider immediate treatment
- RAPD: if present, consider immediate treatment
- Progression in any of the above findings over time

Investigations

- Intraocular pressure: check with a tonometer if available

CT orbits and brain: do not delay intervention for CT if clinically suggestive of vision-threatening retrobulbar haemorrhage.

Figure 30. Retrobulbar haematoma causing globe proptosis. The involved globe appears smaller because it has been pushed superiorly or inferiorly out of the CT slice.⁵



Important differentials

- Open globe injury

Initial treatment



[Video - Canthotomy and cantholysis](#)

1. Topical anaesthetic drops: repeat until no sting on instillation.
2. Subcutaneous local anaesthetic with adrenaline, (e.g. 2% lignocaine with adrenaline) to lateral upper and lower eyelid insertions, deeply to reach the inner aspect of the lateral orbital rim and subconjunctivally if possible. Always point away from the globe.
3. Use artery clamp to clamp over lateral canthus (extending along the eyelid in a 'Cleopatra line') for several seconds.
4. Use sharp-tipped scissors to cut laterally for 1–2cm along the clamped line.

5. Hold the lower lid taught with forceps and blunt dissect between the orbicularis oculi muscle and lateral canthal tendon.
6. Strum the closed scissors over the tendon (anteroposterior). When the lateral canthal tendon has been identified, place each blade of the scissors on either side, (i.e. one in the conjunctival fornix and the other in the pocket between orbicularis and tendon) aiming inferiorly and cut.
7. Ensure the lower lid is lax with eyelids readily openable.
8. Apply Chlorsig ointment and an absorbent dressing.
9. Continue pupil and hourly vision observations.

Specific communication checklist

Consider the following:

- ☒ When did the injury occur?
- ☒ Are there other systemic or head injuries?
- ☒ Is the patient on anticoagulants?
- ☒ Do/did you need to perform canthotomy and cantholysis IMMEDIATELY (dependent on examination findings as above)?

Notes

Consider the following:

- Visual outcomes are better in some case series if canthotomy and cantholysis are performed within 2 hours of injury.
- When examining a CT of the orbits, check both the axial and coronal slices using soft tissue windows. Hyperdensity around the optic nerve, with proptosis, is suggestive of retrobulbar haemorrhage.
- Orbital compartment syndrome may be worse if there are any minimally displaced orbital fractures. A significant 'blow-out' fracture will usually decompress the orbit.
- The main indication for a canthotomy and cantholysis is evidence of end-organ compromise, e.g. reduced visual acuity, an RAPD or evolving motility disturbance.

Acute visual disturbance



Acute visual disturbance

Third (3rd) cranial nerve palsy

Seek an urgent referral to an ophthalmologist <24hr.

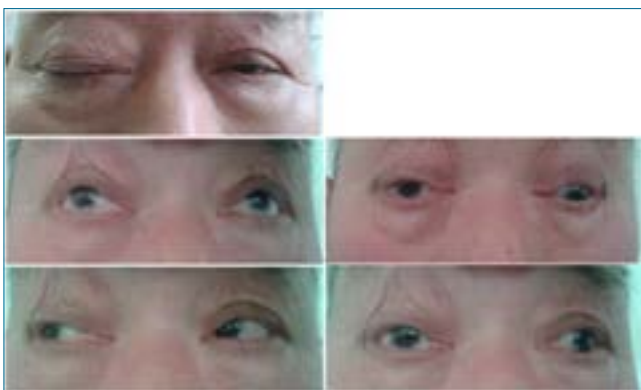

Giant cell arteritis (GCA) is a cause of an isolated 3rd cranial nerve palsy and, if missed, can lead to irreversible blindness in one or both eyes. You must specifically ask the patient about GCA symptoms and document this in the medical record.

A 3rd cranial nerve palsy can be a sign of raised intracranial pressure. You must ask about headache symptoms and examine the optic disc for signs of optic disc swelling.

Don't forget to check the other cranial nerves and ask and look for any other neurological deficits.

Figure 31. Images show right ptosis and 3rd cranial nerve palsy. The right eyelid is being pulled up.⁶



History findings

- Vertical and horizontal diplopia (double vision): note patient may not experience any double vision if they are experiencing complete ptosis
- Complete/partial ptosis
- May have headache and pain
- In patients >60 years, enquire specifically about GCA symptoms

Examination findings

- Ptosis (complete/partial)
- Pupil (may or may not be dilated)
- Ocular motility: the eye looks down and out in primary gaze suggests ophthalmoplegia except for abduction and intorsion
- Examine the remainder of cranial nerves to determine if isolated 3rd cranial nerve palsy or part of multiple cranial nerve palsies

Investigations

- Cardiovascular risk factor work-up
- Fine-cut CTA of Circle of Willis, looking for aneurysm with pupil involvement

Important differentials

- Pituitary apoplexy
- Posterior communicating artery aneurysm
- Vasculitis
- Thyroid eye disease
- Myasthenia gravis
- Horner's syndrome (partial ptosis and normal motility)
- Compression neoplasm

Initial treatment

- Liaise with neurology
- Inform the patient that it is illegal to drive while experiencing diplopia

Specific communication checklist

Consider the following:

- ☒ Presenting complaint: timing, worsening/improving and monocular/binocular
- ☒ Past ocular/medical history
- ☒ Visual acuity (with pinhole if not 6/6)
- ☒ Visual fields (by confrontation)
- ☒ Pupil examination: anisocoria and relative afferent pupillary defect (RAPD)
- ☒ Red reflex
- ☒ Dilated retinal examination
- ☒ Eyelid examination findings (complete/partial ptosis)
- ☒ Ocular motility findings

Fourth (4th) cranial nerve palsy

Seek an urgent referral to an ophthalmologist <24hr.



Giant cell arteritis (GCA) is a cause of an isolated 4th cranial nerve palsy and, if missed, can lead to irreversible blindness in one or both eyes. You must specifically ask the patient about GCA symptoms and document this in their medical record.

A 4th cranial nerve palsy can be a sign of raised intracranial pressure. You must ask about headache symptoms and examine the optic disc for signs of optic disc swelling.

Don't forget to check the other cranial nerves and ask and look for any other neurological deficits.

History findings

Consider the following:

- Vertical and/or torsional diplopia: the patient may describe that images appear tilted/objects appear in their vision and as leaning to one side.
- Ask about the onset, duration and improvement/worsening.
- Ask about a history of trauma, head injury and falls.
- Ask about cardiovascular risk factors, particularly diabetes.
- Ask about the presence of any GCA symptoms.

Examination findings

- Visual acuity
- Check for RAPD (or RAPD with orbital apex/cavernous sinus lesion)
- Evidence of head tilt (consider posture and compare with old photos to determine chronicity)
- Extraocular movement examination
- Examine the remainder of cranial nerves to determine if isolated 4th nerve palsy or part of multiple cranial nerve palsies

Investigations

- Cardiovascular risk factor work-up
- Neuroimaging (CT brain)

Important differentials

- GCA
- Thyroid eye disease
- Myasthenia gravis
- Microvascular
- Trauma
- Congenital

Initial treatment

- Depends on the underlying cause
- Liaise with neurology
- Inform the patient that it is illegal to drive while experiencing diplopia

Specific communication checklist

Consider the following:

- ☒ Presenting complaint: timing, worsening/improving and monocular/binocular
- ☒ Past ocular/medical history (particularly diabetes and how well it has been managed)
- ☒ Visual acuity
- ☒ Visual fields (by confrontation)
- ☒ Pupil examination (anisocoria or presence of RAPD)
- ☒ Red reflex

Sixth (6th) cranial nerve palsy

Seek an urgent referral to an ophthalmologist <24hr.

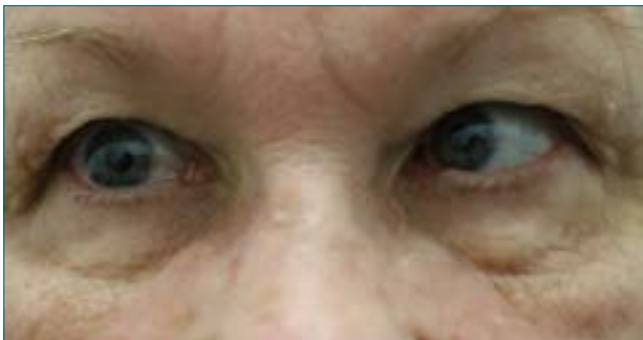

Giant cell arteritis (GCA) is a cause of an isolated 6th cranial nerve palsy and if missed can lead to irreversible blindness in one or both eyes. You must specifically ask the patient about GCA symptoms and document this in their medical record.

A 6th cranial nerve palsy can be a sign of raised intracranial pressure. You must ask about headache symptoms and examine the optic disc for signs of optic disc swelling.

Don't forget to check the other cranial nerves and ask and look for any other neurological deficits.

Figure 32. Patient with 6th cranial nerve palsy.⁷



History findings

Consider the following:

- Horizontal diplopia (double vision) presents as worse for distance than near, and worse looking towards the affected side. The patient may describe double vision whilst driving, watching television or looking out the window.
- Assess for any headache, morning nausea or vomiting (raised intracranial pressure).
- Assess for any GCA symptoms.

Examination findings

- Visual acuity
- Extraocular movements: check for limited abduction and other directions of gaze
- Pupils normal/not normal: anisocoria or RAPD
- Eyelid positions (no ptosis)
- Exclude swollen optic discs (6th cranial nerve palsy may be caused by raised intracranial pressure)
- Examine the remainder of cranial nerves to determine if isolated 6th cranial nerve palsy or part of multiple cranial nerve palsies

Investigations

- Cardiovascular risk factor work-up
- CT brain
- Urgent ESR and CRP blood tests if GCA is suspected

Important differentials

- GCA
- Raised intracranial pressure (e.g., space-occupying lesions)
- Myasthenia gravis
- Trauma

Initial treatment

- Depends on the underlying cause
- Liaise with neurology
- Inform the patient that it is illegal to drive while experiencing diplopia

Specific communication checklist

Consider the following:

- ☒ Presenting complaint: timing, worsening/improving and monocular/binocular
- ☒ Past ocular/medical history (particularly diabetes and how well it has been managed)
- ☒ Visual acuity
- ☒ Visual fields (by confrontation)
- ☒ Pupil examination: anisocoria and RAPD
- ☒ Red reflex
- ☒ Ocular motility looking for difficulty abducting the eye, (i.e. looking away from the nose)

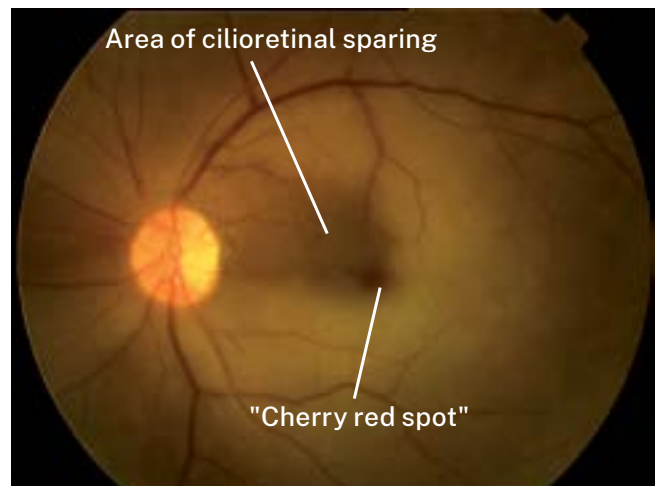Central retinal artery occlusion (CRAO)

Seek an immediate referral to an ophthalmologist.



If the patient has giant cell arteritis (GCA) symptoms, urgent blood tests including ESR and CRP should be ordered.

Figure 33. Area of cilioretinal sparing (top line) and 'cherry red spot' (lower line).



History findings

- Sudden, painless and persistent loss of vision
- GCA symptoms if >50 years of age
- Cardiovascular risk factors

Examination findings

- Poor acuity (may have central sparing)
- Marked RAPD
- Fundus examination: may have minimal signs on fundoscopy
- Pale retina with a cherry red spot and arteriolar and venular narrowing
- Abnormal temporal artery (if suspected GCA)

Investigations

- GCA may cause CRAO: check ESR, CRP and FBC
- Cardiovascular risk factor work-up
- Important differentials
- GCA may co-exist with CRAO

Initial treatment

- Urgent discussion with the ophthalmology team, especially within 4 hours of the onset of symptoms, as certain sight-saving treatments may be attempted

Specific communication checklist

Consider the following:

- ☒ Presenting complaint: timing, worsening/improving and monocular/binocular
- ☒ Past ocular/medical history (particularly diabetes) and how well it has been managed
- ☒ Visual acuity
- ☒ Visual fields (by confrontation)
- ☒ Pupil examination: anisocoria and RAPD
- ☒ Red reflex

GCA symptom list

- Polymyalgia rheumatica
- New onset headache (often temporal)
- Scalp tenderness
- Jaw claudication
- Tongue claudication
- Fever and night sweats
- Loss of weight
- Generalised muscle pain and weakness
- Possible diplopia (double vision) or transient visual loss

Central retinal vein occlusion (CRVO)

Seek immediate referral by phone to an ophthalmologist.



Check for high blood pressure.

Figure 34. From top to bottom: dilated tortuous veins; disc swelling; cotton wool spots; intra-retinal haemorrhage (visible in all four quadrants).

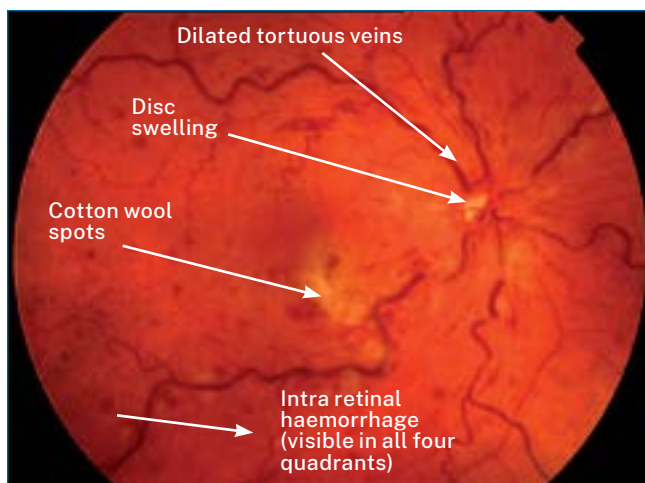
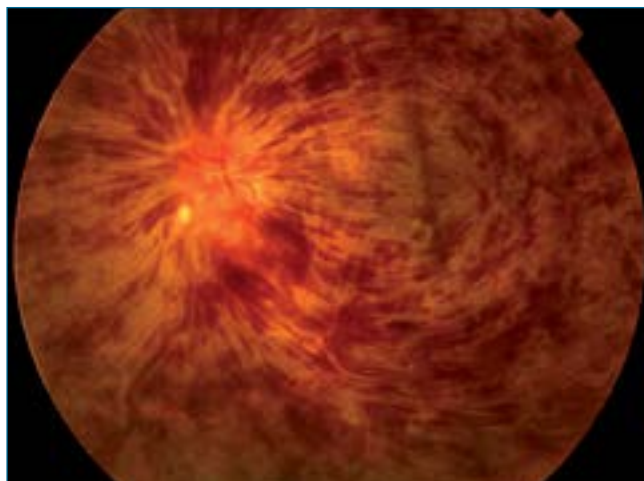


Figure 35. Severe CRVO: haemorrhages obscure much of fundus detail.



History findings

- Sudden and painless loss of vision
- Cardiovascular risk factors
- Increasing age
- Glaucoma

Examination findings

- Visual acuity
- Pupil examination: important prognostic factor (RAPD)
- May see prominent iris vessels and red eye (if long-standing)
- Fundus examination shows multiple areas of haemorrhage
- Intraocular pressure
- Blood pressure

Investigations

- Blood glucose
- Lipids

Important differentials

- Vitreous haemorrhage
- Central retinal artery occlusion
- Giant cell arteritis (GCA)
- Malignant hypertension (preeclampsia in gravid women)

Initial treatment

- Discuss the case with the ophthalmology team for referral urgency
- Screen for diabetes and hypertension

Specific communication checklist

Consider the following:

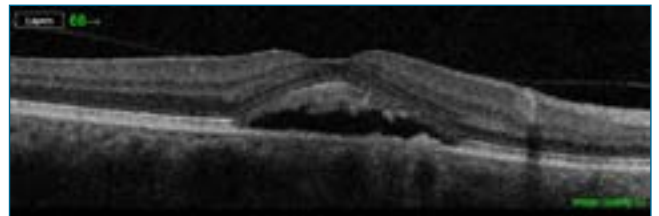
- ☒ Presenting complaint: timing, worsening/improving and monocular/binocular
- ☒ Past ocular/medical history (particularly diabetes) and how well it has been managed
- ☒ Visual acuity
- ☒ Visual fields (by confrontation)
- ☒ Pupil examination: anisocoria and RAPD
- ☒ Red reflex
- ☒ Dilated retinal examination
- ☒ Intraocular pressure

Central serous chorioretinopathy



Consider other diagnoses if significantly reduced vision or an elderly patient.

Figure 36. Central serous retinopathy in a retina, imaged using optical coherence tomography (OCT; vitreous side is at top of image).⁸



History findings

- Usually young men with a Type A personality
- Central scotoma, metamorphopsia
- May have had a previous episode
- Corticosteroid (any form) use, including topical or inhaled

Examination findings

- Reduced visual acuity to around 6/9 or 6/12, improving a little with pinhole (Amsler grid shows a relative scotoma or distortion of lines)
- May present with hyperopic refractive shift/trouble reading, micropsia and colour vision changes
- Ocular examination otherwise normal

Important differentials

- Malignant hypertension
- Choroidal neovascularisation
- Macular haemorrhage
- Macula-off retinal detachment

Specific communication checklist

Consider the following:

- ☒ Presenting complaint: timing, worsening/improving and monocular/binocular
- ☒ Past ocular/medical history (particularly diabetes) and how well it has been managed
- ☒ Visual acuity
- ☒ Visual fields (by confrontation)
- ☒ Pupil examination: anisocoria and RAPD
- ☒ Red reflex
- ☒ Dilated retinal examination if instructed
- ☒ Amsler grid finding

Dry eye/exposure keratopathy

Dry eye is a common chronic ocular condition that is often caused by, or coexists with, other ocular diseases. Dry eye may cause temporary, reversible and minor acute visual disturbance.

Figure 37. Dry eye showing diffuse punctate staining with fluorescein.

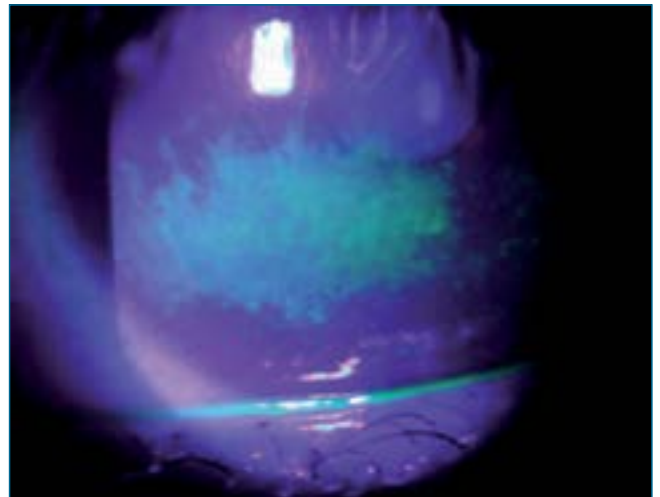
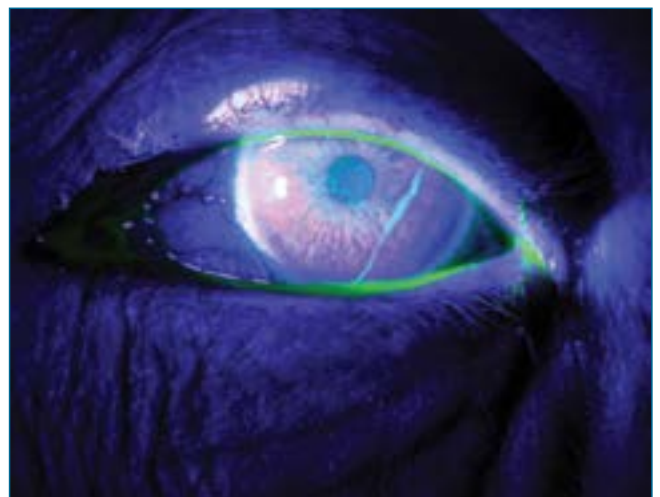


Figure 38. Mucus strand is also visible across the cornea.



History findings

- Sensation of dry eye, eye pain and intermittent blurred vision that improves with blinking or lubricating drops
- Symptoms often worsen in the evening, in air-conditioned or windy environments, and with tasks requiring prolonged concentration (with reduced blink rate)
- Usually bilateral

Examination findings

Consider the following:

- Visual acuity may be slightly reduced (6/6–6/12) and may improve with lubricating drops.
- Punctate fluorescein staining in interpalpebral fissure (lower third of cornea). Staining may vary from no staining or a few punctate erosions, to severe diffuse corneal and conjunctival staining.
- Coexisting posterior blepharitis is often present.

Important differentials

- Chemical burn
- Eyedrop toxicity (especially preserved drops)
- Contact lens-related problem (overwear or solution sensitivity)
- Exposure keratopathy
- Flash burn
- Microbial keratitis

Initial treatment

- Lubricating drops, gels or ointments prn (preserved or preservative-free)
- Reduce exposure to drying conditions (see History section above)
- Treat any co-existing blepharitis

Specific communication checklist

Consider the following:

- ☒ Presenting complaint: timing, worsening/improving and monocular/binocular
- ☒ Past ocular/medical history (particularly diabetes) and how well it has been managed
- ☒ Visual acuity
- ☒ Visual fields (by confrontation)
- ☒ Pupil examination: anisocoria and RAPD
- ☒ Red reflex
- ☒ Dilated retinal examination

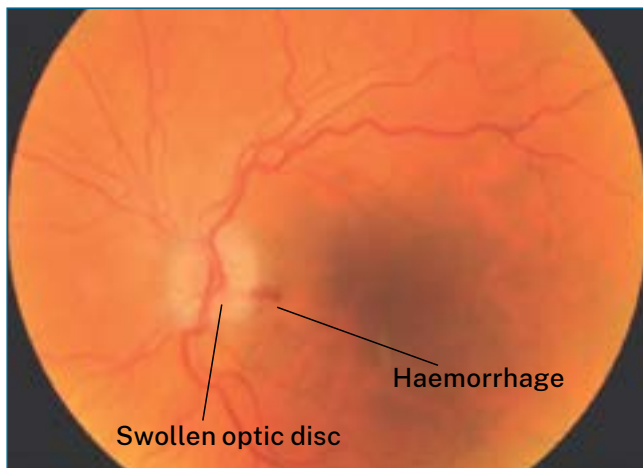
Giant cell arteritis (GCA)/ anterior ischaemic optic neuropathy (AION)

Seek immediate referral by phone to an ophthalmologist.



- Sudden profound loss of vision
- Constitutional symptoms of giant cell arteritis (GCA)
- History of intermittent visual loss
- Age >50yrs

Figure 39. Swollen and pale optic disc (shown left) with a disc margin haemorrhage (shown right).



History findings

- Affects patients older than 50 years of age
- May have polymyalgia rheumatica
- New onset headache (often temporal)
- Scalp tenderness
- Jaw claudication
- Tongue claudication
- Fever and night sweats
- Weight loss
- May have diplopia (double vision) or transient visual loss

Examination findings

May include any or all of the following:

- RAPD
- Poor visual acuity, often counting fingers or light perception (may also be normal)
- Tender and non-pulsatile temporal artery
- Swollen pale optic disc

Investigations

- Immediate ESR and CRP (both/either may be elevated)
- FBC (high platelet count), EUC, LFT and BSL (in planning for steroid treatment)
- Plan for temporal artery biopsy (within 1 week)

Important differentials

- Central retinal artery occlusion (CRAO)
- Non-arteritic anterior ischaemic optic neuropathy (AION)

Initial treatment

Due to the potential risk of severe and irreversible blindness, urgent intravenous corticosteroids should be considered if the diagnosis is likely, especially if the patient has visual symptoms or a demonstrated loss of vision.

Urgent referral is required to a rheumatologist and an ophthalmologist (especially if any visual symptoms or visual loss).

Specific communication checklist

Consider the following:

- ☒ Presenting complaint: timing, worsening/improving and monocular/binocular
- ☒ Ask the patient about GCA symptoms
- ☒ Past ocular/medical history (particularly diabetes and how well it has been managed)
- ☒ Visual acuity
- ☒ Visual fields (by confrontation)
- ☒ Pupil examination: anisocoria and RAPD
- ☒ Red reflex

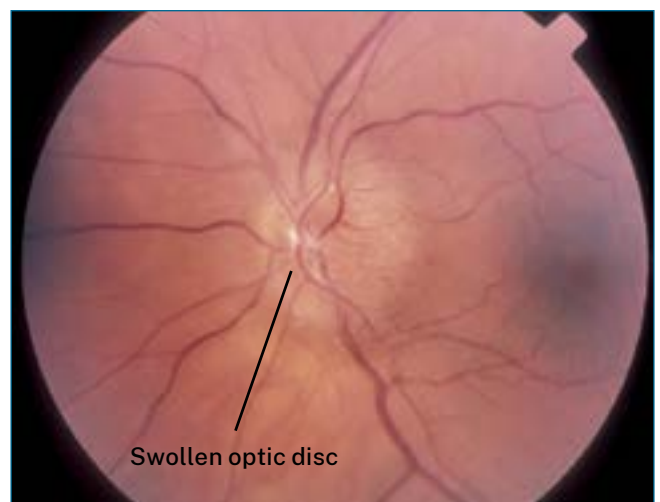
Idiopathic intracranial hypertension (IIH): transient visual obscuration

Seek immediate referral by phone to an ophthalmologist < 24hr.



May lead to permanent loss of vision, severe headache, neurological signs and drowsiness.

Figure 40. Optic disc swelling (note blurred disc margins).



History findings

- Headache, worse in the morning or lying supine
- Transient visual obscuration (seconds)
- Pulsatile tinnitus
- Medication such as oral contraceptive pills, vitamin A derivatives and tetracyclines
- Most commonly affects young, overweight females

Examination findings

- Visual acuity is often normal unless advanced
- Visual field testing (by confrontation) and needs automated perimetry in private rooms, public hospital or other eye service
- Pupil examination (RAPD may be absent if symmetrical optic nerve damage)
- Extraocular movement (may have 6th cranial nerve palsy or palsies)
- Increased body mass index (weigh the patient)
- Swollen optic disc/s

Investigations

- Blood pressure
- Brain MRI/MRV diagnostics
- Lumbar puncture to check opening pressure

Important differentials

- Venous sinus thrombosis
- Intracranial space-occupying lesion
- Thyroid eye disease
- Lymphoma
- Giant cell arteritis (GCA) if >50 years old

Initial treatment

- Liaise with the ophthalmology team urgently if the optic nerve is compromised (reduced vision, RAPD or colour vision change)

Section communication checklist

Consider the following:

- ☒ Presenting complaint: timing, worsening/improving and monocular/binocular
- ☒ Past ocular/medical history (particularly diabetes) and how well it has been managed
- ☒ Visual acuity
- ☒ Visual fields (by confrontation) and also need automated perimetry at private rooms, public hospital or other eye service
- ☒ Pupil examination: anisocoria or RAPD
- ☒ Red reflex

Specific communication checklist

Consider the following:

- ☒ Field loss
- ☒ Optic disc appearances
- ☒ Weight and BMI

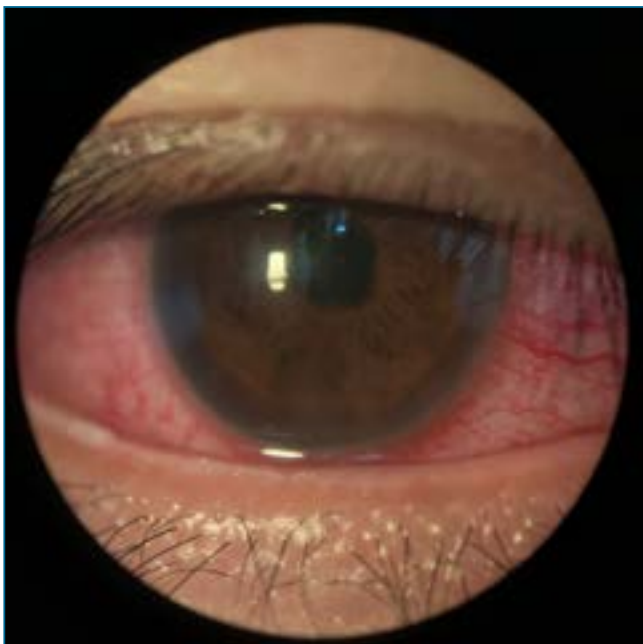
Intermittent angle closure/ acute angle closure

Seek an immediate referral to an ophthalmologist.



Reduced vision and unwell, (e.g. nausea and vomiting).

Figure 41. Conjunctival vessels dilated at the corneal edge (ciliary flush and circumcorneal flush) and hazy cornea characteristic of acute angle closure, where intermittent is a variant.⁹



History findings

- Usually South East Asian background
- May have significant glare, a history of eye pain or blurry vision in dim light
- Uncommon in patients who have had cataract surgery

Examination findings

Consider the following:

- Reduced visual acuity, abnormal red reflex, +/- RAPD (if developed retinal complications)
- May also have fixed and dilated pupil
- The cornea appears cloudy
- Raised intraocular pressure (if it can be measured) and the globe may feel firm on palpation.

Initial treatment

- Liaise with an ophthalmologist

Section communication checklist

Consider the following:

- ☒ Presenting complaint: timing, worsening/ improving and monocular/binocular
- ☒ Past ocular/medical history
- ☒ Visual acuity
- ☒ Visual fields (by confrontation)
- ☒ Pupil examination: anisocoria and RAPD
- ☒ Red reflex

Specific communication checklist

Consider the following:

- ☒ Slit lamp examination
- ☒ Check for a sulphur allergy if treatment with acetazolamide (diamox) is considered

Notes

Avoid dilating patients with suspected narrow angles.

Lens subluxation



History of ocular trauma and systemic associations, such as Marfan syndrome.

History findings

- Reduced vision
- Monocular diplopia (double vision)
- History of eye/head trauma
- Pseudoexfoliation syndrome
- Ocular surgery
- Medical history (Marfan syndrome or homocystinuria)

Examination findings

- Visual acuity
- Check intraocular pressure if possible: RAPD should be absent
- Dilated examination, if instructed by the ophthalmology team, shows a subluxed lens or intraocular lens implant
- Assess for associated ocular injury if caused by trauma
- Physical examination to check features of Marfan syndrome

Investigations

- Marfan syndrome or homocystinuria work up if suspected clinically

Important differentials

- Acute angle closure crisis
- Uveitic glaucoma
- Eccentric pupil
- Penetrating eye injury

Initial treatment

- Consult the ophthalmology team to establish the diagnosis, underlying cause and management

Specific communication checklist

Consider the following:

- ☒ Medical history
- ☒ Ocular history
- ☒ Visual acuity
- ☒ Pupil assessment
- ☒ Anterior segment findings (dilated examination if instructed by the ophthalmology team) and intraocular pressure if able to obtain
- ☒ Physical examination to look for Marfan syndrome features

Macular haemorrhage in wet age-related macular degeneration

Seek an immediate referral to an ophthalmologist.



History of age-related macular degeneration.

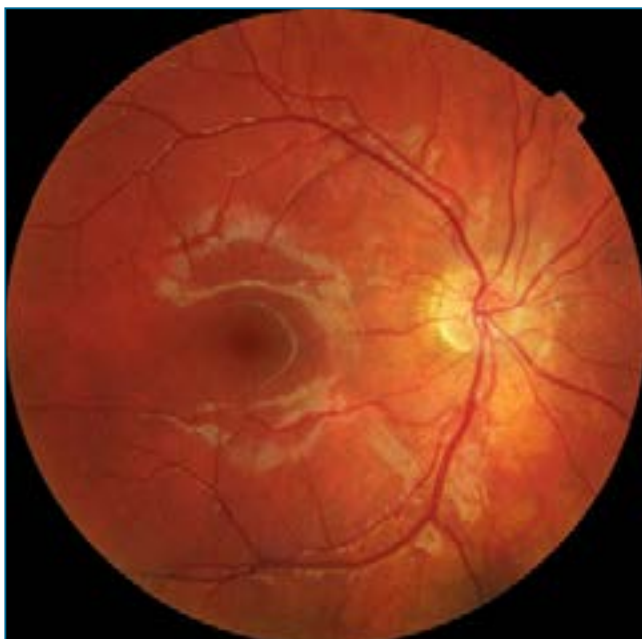History findings

- Sudden, persistent, unilateral, painless loss of central vision
- History of macular degeneration (may be on intravitreal anti-VEGF injections)
- May be on anticoagulants

Examination findings

- Reduced visual acuity with relatively intact or unaffected peripheral vision
- Central scotoma on [Amsler grid](#)
- Pupil examination: RAPD may be present

Figure 42. Central scotoma on Amsler grid.



Important differentials

- Central retinal vein occlusion
- Central retinal artery occlusion
- Haematological malignancy
- Diabetic retinopathy
- Other macular pathology

Initial treatment

- Contact an ophthalmologist to establish the diagnosis

Section communication checklist

Consider the following:

- ☒ Presenting complaint: timing, worsening/ improving and monocular/binocular
- ☒ Past ocular/medical history (particularly diabetes) and how well it has been managed
- ☒ Visual acuity
- ☒ Visual fields (by confrontation)
- ☒ Pupil examination: anisocoria and RAPD
- ☒ Red reflex
- ☒ Dilated retinal examination

Specific communication checklist

Consider the following:

- ☒ Medical history: anticoagulant use
- ☒ Peripheral vision
- ☒ [Amsler grid](#) finding

Macular pathology

The macula is the central region of the retina and is responsible for central vision. People with macular conditions are usually symptomatic, often with reduced visual acuity on Snellen chart testing. The onset can be acute or chronic. A detailed posterior segment examination, including dilation of the pupils and, often, the use of imaging techniques such as optical coherence tomography, will aid the diagnosis of the specific type of macular pathology.

Conditions to consider include macular haemorrhage, macular hole, epiretinal membrane, dry age related macular degeneration, central serous retinopathy, macular oedema due to diabetic retinopathy and post-operative macular oedema.

Migraine



Poor vision, neurological symptoms, age >50 and visual disturbance of more than 1 hour.

History findings

- Headache (unilateral)/throbbing headache
- Nausea and vomiting
- Visual aura (typically precedes migraine onset and lasts 15–20 minutes)
- Flashes after visual aura
- Central scotoma
- Other neurological symptoms

Examination findings

- Normal ocular examination
- May present with a scotoma on visual field assessment whilst experiencing a migrainous aura

Important differentials

- Acute angle closure
- Malignant hypertension
- Raised intracranial pressure
- Meningitis
- Central nervous system lesion

Initial treatment

- Consult neurology team

Specific communication checklist

Consider the following:

- ☒ Headache
- ☒ Medical history and neurological symptoms
- ☒ Visual acuity, RAPD and red reflex
- ☒ Ocular movement

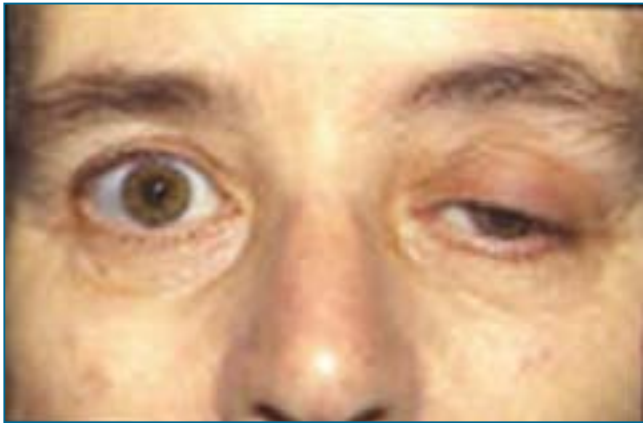Myasthenia gravis

Seek immediate referral by phone to an ophthalmologist < 24hr.



May be associated with respiratory distress or difficulty swallowing.

Figure 43. Patient with ocular myasthenia gravis.¹⁰



History findings

- Double vision and ptosis
- Variability of symptoms (worse towards the end of the day)
- Systemic symptoms (dysphagia, limb weakness and difficulty breathing)
- Fatigability (particularly of the eyelids causing variable ptosis)

Examination findings

- Ptosis
- Ocular motility is abnormal, but not 3rd, 4th or 6th cranial nerve palsy pattern (although myasthenia gravis can mimic these)
- Ice test
- Pupil examination (should be normal; consider another diagnosis if not)
- Fatigability of lids with sustained up-gaze (1–2 minutes)

Investigations

- Anti-Ach receptor (AChR) antibody
- Anti-MuSK antibody (muscle-specific kinase)
- Thyroid function tests

Important differentials

- Thyroid eye disease
- Other cranial nerve palsies
- Orbital lesions

Initial treatment

- Discuss with neurology
- Ophthalmology consultation regarding diplopia (double vision) and ptosis management

Section communication checklist

Consider the following:

- ☒ Presenting complaint: timing, worsening/ improving and monocular/binocular
- ☒ Past ocular/medical history (particularly diabetes) and how well it has been managed
- ☒ Visual acuity
- ☒ Visual fields (by confrontation)
- ☒ Pupil examination: anisocoria and RAPD
- ☒ Red reflex

Specific communication checklist

Consider the following:

- ☒ Medical, ocular history (especially any variability of symptoms and fatigability)
- ☒ Pupil assessment
- ☒ Extraocular movement assessment
- ☒ Ptosis measurement

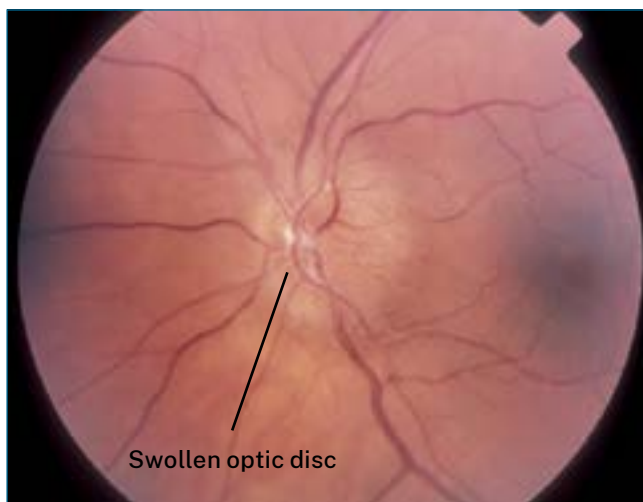
Optic neuritis

Seek an immediate referral by phone to an ophthalmologist < 24hr.



Atypical optic neuritis features (consider other diagnoses): bilateral, rapid onset, systemic symptoms, male, Southeast Asian background, age >50 (consider giant cell arteritis (GCA) and profound visual loss).

Figure 44. Optic neuritis shows a swollen optic disc and blurred disc margins.



History findings

- Painless vision loss over hours to days
- Vision loss can be subtle or profound (atypical)
- Reduced visual acuity (blurring), reduced colour vision and contrast vision
- Usually unilateral but may rarely be bilateral
- Often affects females aged 18–45 years old
- Retrobulbar pain is usually associated with eye movement and can occur before visual loss
- May have other focal neurological symptoms relating to demyelination

Examination findings

- Decreased visual acuity (test with pinhole if not 6/6)
- Pupil examination (RAPD) tested prior to dilation
- Decreased colour vision
- Possible patchy scotoma but any field defect is possible and may be difficult to elicit on confrontation
- Other focal neurological signs relating to demyelination are possible
- Check blood pressure

Investigation

- Discussion with neurology if medical imaging is needed
- Further investigations as per the neurology team
- Consider inflammatory and infective causes of optic neuritis

Important differentials

Consider the following:

- Neuromyelitis optica (in Asian populations with profound visual loss and bilateral involvement).
- GCA is possible (in older patients).
- Vasculitis is possible.
- Other causes of swollen optic disc, (e.g. GCA, raised intracranial pressure, idiopathic intracranial hypertension, systemic hypertension, central retinal vein occlusion, thyroid eye disease and diabetic papillitis).

Initial treatment

- Discuss with the neurology team for further investigations

Section communication checklist

Consider the following:

- ☒ Presenting complaint: timing, worsening/improving and monocular/binocular
- ☒ Past ocular/medical history (particularly diabetes) and how well it has been managed
- ☒ Visual acuity
- ☒ Visual fields (by confrontation)
- ☒ Pupil examination: anisocoria and RAPD
- ☒ Red reflex
- ☒ Dilated retinal examination if instructed

Specific communication checklist

Consider the following:

- ☒ Neurological examination
- ☒ Extraocular movements
- ☒ Appearance of optic disc

Posterior vitreous detachment (PVD)

Seek an immediate referral by phone to an ophthalmologist < 24hr.



Consider other diagnoses if there is visual acuity loss or visual field loss.

History findings

Consider the following:

- Peripheral flashes (usually temporal) and differentiate from migraine 'flashes', which last several minutes, tend to scintillate, spread across the visual field, may be multi-coloured and are often associated with an adjacent scotoma or blurring of vision.
- Patients often cannot discern whether monocular or binocular in origin. Migraines sometimes do not have associated headaches, nausea or vomiting.
- The presence of floaters.
- PVD is usually unilateral and painless. Possible precipitating mild head or eye trauma.
- No neurological symptoms.

Examination findings

- Visual acuity
- Check red reflex (vitreous blood may be seen floating behind the lens; retinal detachment can cause loss of the red reflex)
- Visual fields (by confrontation)
- Pupil examination: RAPD should not be present
- Dilated retinal examination

Important differentials

- Retinal tear/break
- Retinal detachment

Initial treatment

- Liaise with an ophthalmologist

Section communication checklist

Consider the following:

- ☒ Presenting complaint: timing, worsening/improving and monocular/binocular
- ☒ Past ocular/medical history (particularly diabetes) and how well it has been managed
- ☒ Visual acuity
- ☒ Visual fields (by confrontation)
- ☒ Pupil examination: anisocoria and RAPD
- ☒ Red reflex
- ☒ Dilated retinal examination if instructed

Specific communication checklist

Consider the following:

- ☒ History: peripheral flashes and/or floater/s
- ☒ RAPD or red reflex
- ☒ No other neurological symptoms

Notes

- This is a common condition caused by liquefaction of vitreous with age. It tends to occur in 50–60-year olds.
- The ‘flashes’ symptom reflects active vitreous traction on the retina.
- Complete vitreous detachment can take up to 6 weeks to occur.
- The majority of patients have no long-term consequences from PVD. A small percentage may develop a retinal detachment. Consequently, patients with new onset of flashes or floaters should be examined by an ophthalmologist within 24–48 hours. If there is reduced visual acuity, visual field loss, blood visible in the vitreous or other suspicious findings on history/examination, please liaise with an ophthalmologist as more urgent review may be required.

Retinal tear or detachment

Seek an immediate referral to an ophthalmologist.



Curtaining and loss of vision.

Figure 45. Retinal detachment (macula off).
The lower end of the lines delineates the inferior edge of the retinal detachment. The macula is just involved.

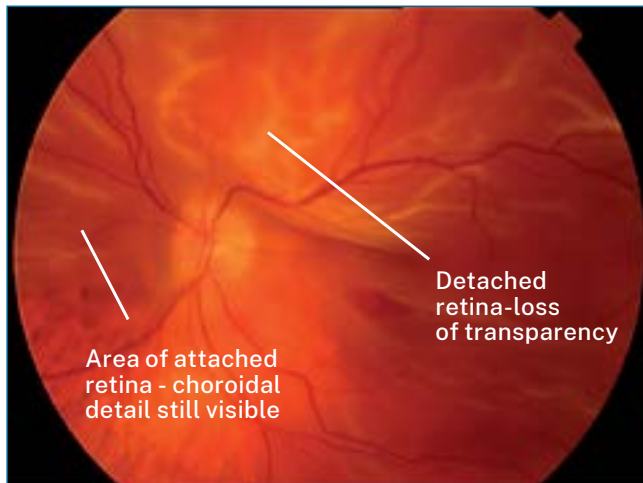
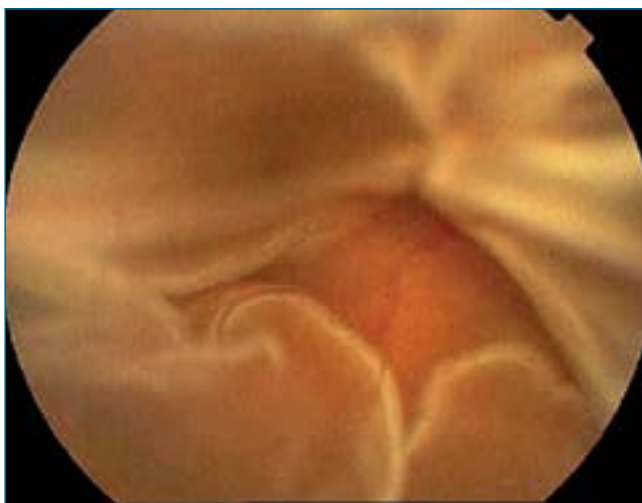


Figure 46. Subtotal retinal detachment.



History findings

Consider the following:

- Painless loss of vision: the patient may have a recent history of increased number of visual floaters and/or visual flashes.
- There may be a 'dark shadow' in the peripheral visual field of the affected eye.
- High-risk groups are patients who are myopic (short-sighted), who have had blunt eye/head trauma and who have a history of retinal detachment or eye procedures

Examination findings

Consider the following:

- Reduced visual acuity if the macula is detached. If not involved ('macula on'), the vision is often 6/6. This is a more urgent condition as the macula can be saved with early surgery.
- Loss of red reflex: a mobile detached retina may be visible on ophthalmoscopy
- Pupil examination is required for RAPD
- Visual field defects that correspond to the area of the detached retina can usually be elicited by confrontation testing
- Often normal anterior segment slit lamp examination
- Dilated retinal examination: it is generally safe to dilate these patients once the above examination has been completed

Important differentials

- Posterior vitreous detachment
- Retinal vein or artery occlusion
- Stroke
- Giant cell arteritis (GCA)
- Optic neuritis
- Diabetic retinopathy (tractional detachment or vitreous haemorrhage)

Initial treatment

- Liaise with ophthalmologist
- Keep the patient nil by mouth for the possibility of emergency surgery

Section communication checklist

Consider the following:

- ☒ Presenting complaint: timing, worsening/improving and monocular/binocular
- ☒ Past ocular/medical history
- ☒ Visual acuity
- ☒ Visual fields (by confrontation)
- ☒ Pupil examination: anisocoria and RAPD
- ☒ Red reflex
- ☒ Dilated retinal examination

Specific communication checklist

Consider the following:

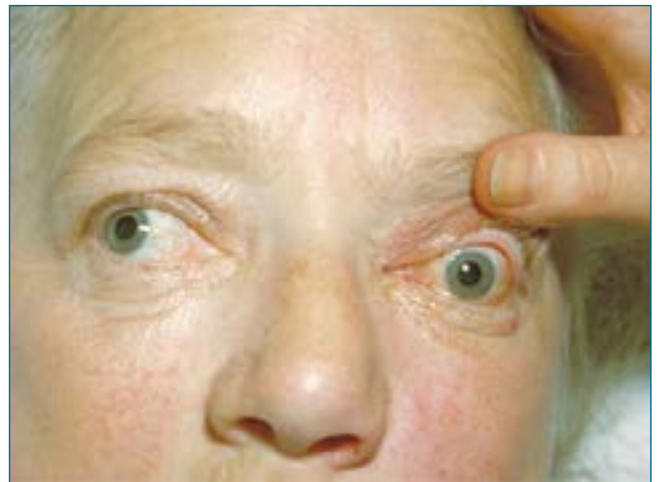- ☒ History and risk factors
- ☒ Prior cataract or other eye surgery
- ☒ Onset of symptoms
- ☒ Fasting time

Thyroid eye disease



Loss of vision or incomplete eyelid closure should prompt an urgent referral to an ophthalmologist.

Figure 47. Bilateral proptosis (exophthalmos), as well as asymmetrical eye alignment indicative of eye muscle neuromuscular involvement.¹¹



History findings

- Known Graves' disease
- Diplopia (double vision), red eye or painful eye
- Blurred vision
- Systemic symptoms of hyperthyroidism
- Smoking history

Examination findings

- Visual acuity
- Proptosis
- Incomplete lid closure
- Strabismus
- Compressive optic neuropathy

- Possible corneal ulcer from exposure of the cornea from incomplete eyelid closure
- Optic nerve function assessment
- RAPD
- Extraocular muscle palsy

Investigations

- Thyroid function test
- CT orbit if proptosis, red eye
- FBC, LFT, EUC and BSL blood tests in planning for corticosteroid treatment

Important differentials

- Orbital cellulitis or trauma
- Orbital tumour

Initial treatment

- Immediate ophthalmology consultation is required if reduced vision (to assess for compressive optic neuropathy) and for urgent treatment (if corneal ulcers present)

Specific communication checklist

Consider the following:

- ☒ Medical, ocular history
- ☒ Visual acuity, red reflex, RAPD and ocular motility

Transient ischaemic attack (amaurosis fugax) or retinal emboli

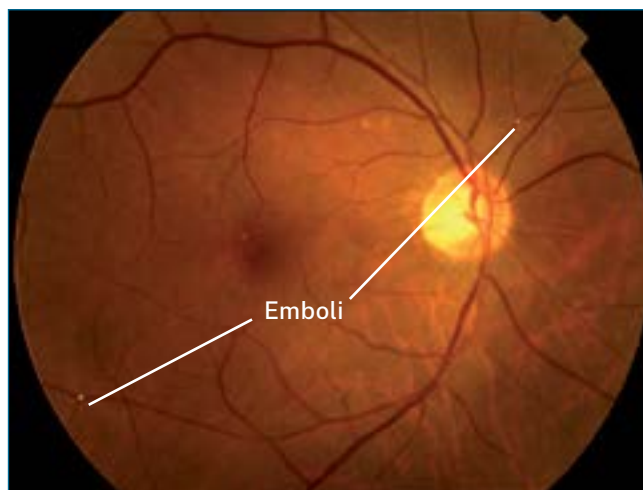
Seek an urgent referral to an ophthalmologist < 24hrs.



Giant cell arteritis (GCA) symptoms, neurological symptoms and recurrent episodes.

Referral to neurology/cardiology or vascular surgery as appropriate. Patients with recurrent episodes of amaurosis fugax require immediate diagnostic and therapeutic intervention.

Figure 48. Transient ischaemic attack. Lines point to visible emboli.



History findings

- Painless, monocular visual loss lasting less than 30 minutes before returning to normal
- Cardiovascular risk factors, including smoking
- History of clotting disorder
- Other neurological symptoms
- History of cardiac arrhythmia
- Anticoagulation therapy

Examination findings

- Usually normal ocular examination findings: fundoscopy may reveal small emboli at the bifurcations of retinal arterioles
- Visual field assessment, (e.g. may have a visual field defect)
- Extraocular movements
- Pupil examination should be normal
- Neurological examination

Investigations

- Assessment of cardiovascular risk factors and guided by a neurologist
- Blood count, electrolytes, lipids and fasting blood glucose
- Investigation for thrombophilia and hypercoagulable state: discuss with haematology (consider if age <50 or relevant history)
- Echocardiogram
- Carotid doppler studies

Important differentials

- GCA
- Vasculitis
- Transient visual obscuration
- Transient blurring of vision: dry eye and vitreous floaters

Initial treatment

- Liaise with physicians

Section communication checklist

Consider the following:

- ☒ Presenting complaint: timing, worsening/improving and monocular/binocular
- ☒ Past ocular/medical history
- ☒ Visual acuity
- ☒ Visual fields (by confrontation)
- ☒ Pupil examination: anisocoria and RAPD
- ☒ Red reflex
- ☒ Dilated retinal examination

Visual pathway lesion

Visual pathway pathology

Patients can present with visual complaints secondary to non-ocular causes. A thorough history and neurological assessment should be performed to consider neuroimaging.

Examples of visual pathway pathologies include:

- Optic neuritis
- Traumatic optic neuropathy
- Giant cell arteritis (GCA)
- Non-arteritic ischaemic optic neuropathy
- Chiasmal lesion
- Pituitary tumour or disease
- Bitemporal hemianopia

Cortical blindness

- Lesions affecting the occipital lobe or other parts of visual pathway
- Diagnoses of exclusion are necessary and require a formal ophthalmology assessment

Amblyopia

Amblyopia, or reduced visual acuity, results from deprivation of optimal visual experience during early childhood. Patients are usually aware of a history of amblyopia or 'lazy eye'.

Functional visual loss

Functional vision loss is a decrease in visual acuity that cannot be accounted for by anatomical or physiological findings. The objective assessments should demonstrate a visual acuity better than subjective visual acuity.

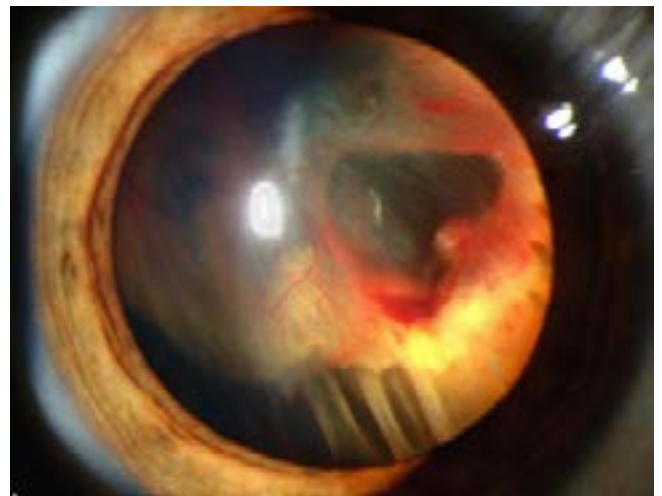
Vitreous haemorrhage

Seek an urgent referral to an ophthalmologist <24hrs.



- Flashes
- Floaters with reduced vision
- Presence of RAPD
- Diabetes
- Age-related macular degeneration (ARMD)
- History of trauma

Figure 49. Slit lamp photograph shows retinal detachment with visible vitreous.¹²



History findings

- Sudden loss of vision or flashes/floaters
- May be on anticoagulants
- History of trauma or diabetes

Examination findings

- Reduced visual acuity: check for RAPD (if developed retinal complications)
- Anterior vitreous red blood cells (visible on slit lamp examination)

Investigations

- Diabetic work up
- Trauma work up (if applicable)

Important differentials

- Retinal detachment
- Retinal tear
- Posterior vitreous detachment
- Proliferative diabetic retinopathy

Initial treatment

- Discussion with ophthalmologist

Section communication checklist

Consider the following:

- ☒ Presenting complaint: timing, worsening/improving or monocular/binocular
- ☒ Past ocular/medical history
- ☒ Visual acuity (with pinhole if not 6/6)
- ☒ Visual fields by confrontation
- ☒ Pupil examination: anisocoria and RAPD
- ☒ Red reflex
- ☒ Dilated retinal examination

Acute red eye or eyelid

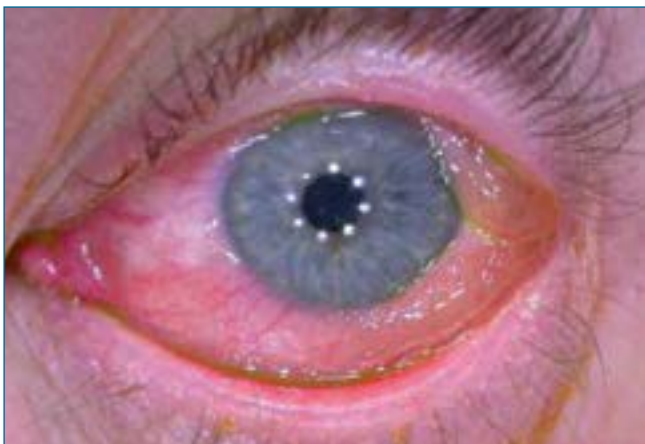

Acute red eye or eyelid

Acute red eye overview

Many conditions can lead to a patient presenting with a red eye. Many of these are self-limiting or will respond to simple treatment.

Figure 50. Acute red eye.



Indicators of more serious pathology

- Pain (as opposed to irritation) and/or reduced vision
- Contact lens use
- Foreign body exposure history (in particular any possibility of penetrating injury)
- Known connective tissue disorders, e.g. risk of keratitis, iritis/uveitis, epi/scleritis and giant cell arteritis (GCA)

Indicators of less serious pathology

- Bilateral red eye, especially in the context of other viral or allergic symptoms (and in the absence of any of the above indicators)

Additional useful distinctions

Assess pain relief after topical anaesthetic drop. If total, this suggests conjunctival irritation or if only partial, consider the ocular disease process.

The presence of corneal epithelial damage (fluorescein uptake) or any loss of corneal clarity.

Conditions are grouped below as disorders, primarily of:

- eyelid and associated structures
- conjunctiva and cornea
- anterior chamber
- globe and orbit

Urgency

Triage urgency is guided by the Department of Health's Summary of ophthalmic emergency predictors (OEP) for the Australasian Triage Scale.

The urgency of ophthalmology review following ED assessment is indicated where relevant.

It is rare for a painless red eye to require an urgent ophthalmological assessment, particularly if vision is normal.



Beware of making the diagnosis of monocular conjunctivitis until more serious eye disease is excluded.

Conjunctival redness can be diffuse or localised.

Use fluorescein to ascertain the nature of any epithelial defect.

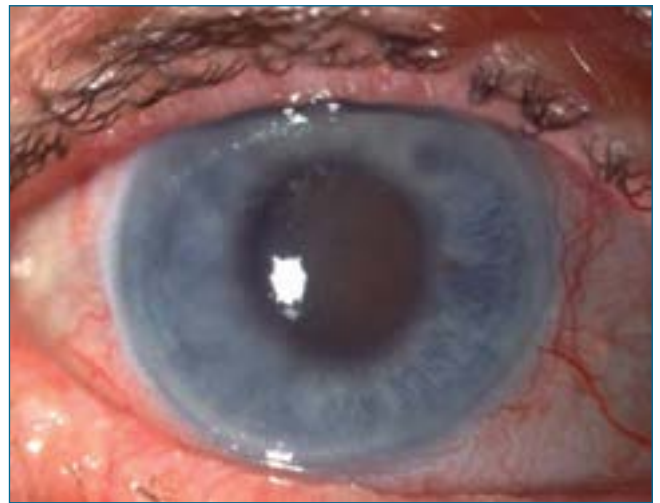Section communication checklist

Consider the following:

- ☒ Onset and duration of symptoms
- ☒ Painful/not painful
- ☒ Distribution of redness (localised or diffuse/involving tarsal conjunctiva)
- ☒ Purely unilateral, or some contralateral symptoms
- ☒ Best (pinhole) visual acuity of each eye
- ☒ Eyelids involvement (red or swollen)
- ☒ Cornea normal or not normal, i.e. cloudy, opacities or fluorescein staining
- ☒ Anterior chamber normal or not normal, i.e. deep, presence of anterior chamber cells, blood or hypopyon
- ☒ Iris normal, i.e. round, equal, reactive pupils with normal iris detail visible
- ☒ Equal red reflexes

Acute angle closure crisis

Figure 51. Acute angle crisis, with cloudy cornea, loss of iris detail, and a fixed mid-dilated pupil.



History findings

- Ocular symptoms include eye ache/pain, cloudy/loss of vision and red eye
- Systemic symptoms include headache, nausea and vomiting

Examination findings

Consider the following:

- The cornea usually has a hazy appearance. The iris details may be difficult to see due to corneal oedema.
- The anterior chamber is shallow. Use a fine slit at 45° on the slit lamp, or shine a torch from the side for irregular semi-dilated pupils.
- The affected eye is very tender and tense to palpation.

Initial treatment

- May require anti-glaucoma drops (see ocular drug section) and an urgent laser procedure

Notes

Digital palpation tonometry can be performed. Using both index fingers to 'ballot' the eyeball under gently-closed eyelids, it is possible to compare the 'hardness' of the eyeball from one eye to the other. If the affected eye has elevated intraocular pressure, then it will feel very hard and firm to palpation (more like a golf ball than a gelatinous ball).

Specific communication checklist

Consider the following:

- ☒ Symptoms are often triggered by dark lighting conditions
- ☒ Has the patient had cataract surgery before? If so, then it is extremely unlikely to be angle closure crisis
- ☒ How firm the globe feels on palpation

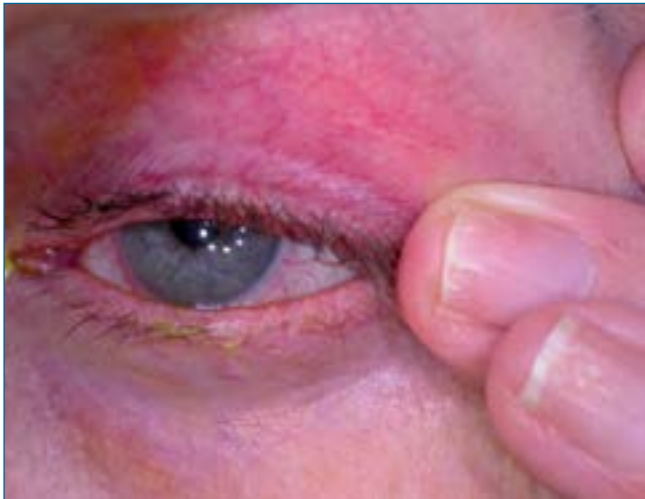Section communication checklist

Consider the following:

- ☒ Onset and duration of symptoms
- ☒ Painful/not painful
- ☒ Distribution of redness (localised or diffuse/involving tarsal conjunctiva)
- ☒ Purely unilateral, or some contralateral symptoms
- ☒ Best (pinhole) visual acuity of each eye
- ☒ Eyelids involvement (red or swollen)
- ☒ Cornea normal or not normal, i.e. cloudy, opacities or fluorescein staining
- ☒ Anterior chamber normal or not normal, i.e. deep, presence of anterior chamber cells, blood or hypopyon
- ☒ Iris normal, i.e. round, equal, reactive pupils with normal iris detail visible
- ☒ Equal red reflexes

Acute blepharitis

Figure 52. Blepharitis.



History findings

- Foreign body sensation, tearing and crusting around the eyes and worse in the morning
- Dry eye symptoms with reading and other tasks and in air-conditioning

Examination findings

- Crusty, red and thickened eyelid margin
- Closer inspection may reveal fine telangiectatic vessels at the lid margin and blocked Meibomian glands

Initial treatment

Consider the following:

- Treat with daily eyelid hygiene and lubrication as required. Instructions for bathing the eyelids are available [here](#).
- Treat with antibiotic ointment if indicated, at night, for 1 month.
- Ophthalmology referral is normally only indicated if associated ocular damage, (e.g. from rubbing or trichiasis).

Notes

- Acute blepharitis may be associated with marginal keratitis, chalazion or dry eyes.
- Blepharitis is localised eyelid margin inflammation, usually with minimal ocular involvement.

Section communication checklist

Consider the following:

- ☒ Onset and duration of symptoms
- ☒ Painful/not painful
- ☒ Distribution of redness (localised or diffuse/involving tarsal conjunctiva)
- ☒ Purely unilateral, or some contralateral symptoms
- ☒ Best (pinhole) visual acuity of each eye
- ☒ Eyelids involvement (red or swollen)
- ☒ Cornea normal or not normal, i.e. cloudy, opacities or fluorescein staining
- ☒ Anterior chamber normal or not normal, i.e. deep, presence of anterior chamber cells, blood or hypopyon
- ☒ Iris normal, i.e. round, equal, reactive pupils with normal iris detail visible
- ☒ Equal red reflexes

Allergic conjunctivitis

Figure 53. Allergic conjunctivitis.

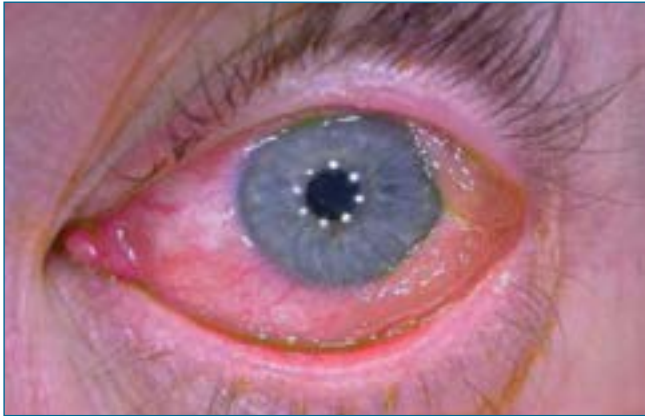
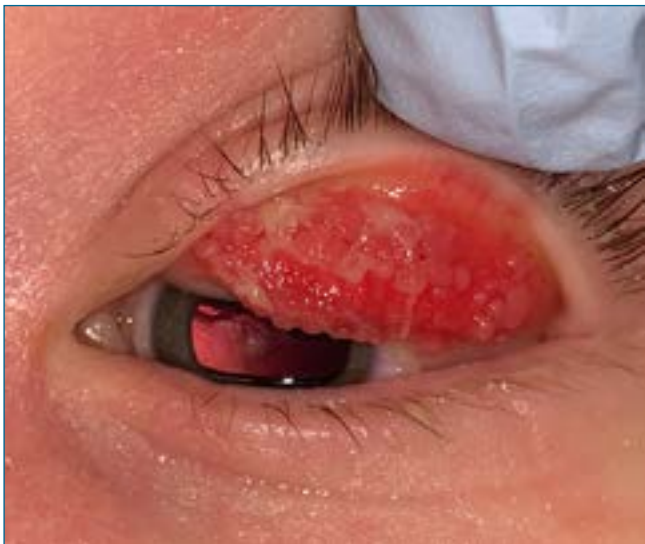

Figure 54. Vernal keratoconjunctivitis: giant papillae of the upper tarsal conjunctiva.¹³



History findings

- Itchiness is the hallmark symptom
- Watery, red eyes may be a symptom
- Atopic history (asthma, eczema, allergic rhinitis and conjunctivitis) and these are often exacerbated together

Initial treatment

- Cool compresses as required
- Ocular lubricating drops, gels or ointments (preservative free) qid available over the counter
- Consider systemic antihistamine or topical antihistamine/mast-cell stabiliser

Notes

Allergic conjunctivitis may be severe and long-standing, and occasionally results in corneal ulcers and scarring.

If symptoms are not adequately treated with the above treatment, consider a non-urgent referral to an ophthalmologist.

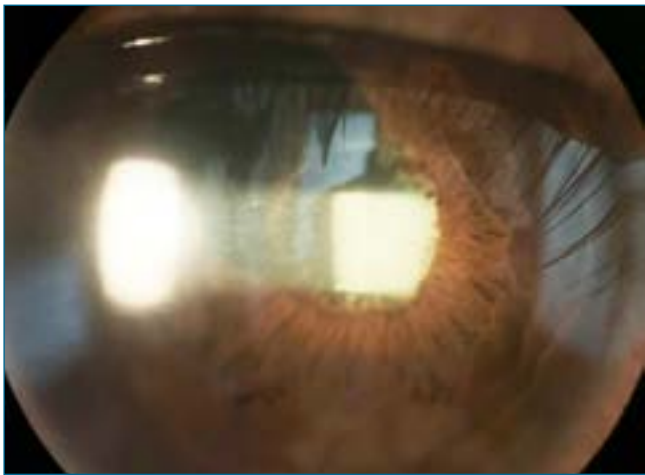
Section communication checklist

Consider the following:

- ☒ Onset and duration of symptoms
- ☒ Painful/not painful
- ☒ Distribution of redness (localised or diffuse/involving tarsal conjunctiva)
- ☒ Purely unilateral, or some contralateral symptoms
- ☒ Best (pinhole) visual acuity of each eye
- ☒ Eyelids involvement (red or swollen)
- ☒ Cornea normal or not normal, i.e. cloudy, opacities or fluorescein staining
- ☒ Anterior chamber normal or not normal, i.e. deep, presence of anterior chamber cells, blood or hypopyon
- ☒ Iris normal, i.e. round, equal, reactive pupils with normal iris detail visible

Iritis (anterior uveitis or an anterior chamber inflammation)

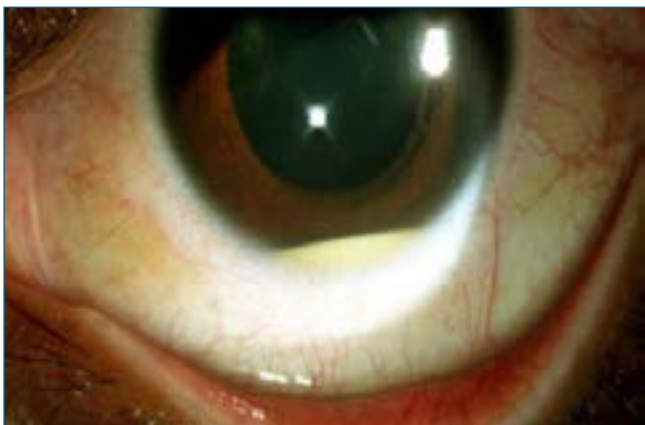Figure 55. Anterior uveitis.¹⁴



History findings

- Red eye
- Pain (usually a deep ache)
- Photophobia
- Timing of onset of symptoms
- If recent intraocular surgery, (e.g. cataract or injections), consider endophthalmitis
- History of autoimmune disease, e.g. vasculitis or rheumatoid arthritis

Figure 56. Slit lamp photograph of hypopyon uveitis.¹⁵



Examination findings

Consider the following:

- Visual acuity may be decreased.
- The eye will often appear diffusely red, although often more marked near the limbus.
- The pupil may be smaller than the contralateral pupil, due to iris spasm. It may be irregular and unreactive to light due to adhesions.
- The anterior chamber may appear cloudy from suspended white blood cells and flare. Look closely for a hypopyon. Assess the cornea for white cell infiltrates (small white opacities indicating bacterial infection).
- Check for fluorescein staining.
- Check intraocular pressure.

Important differentials

- Endophthalmitis
- Uveitis (iritis)
- Severe corneal inflammation from bacterial or viral infection, or chemical burn
- Intraocular foreign body

Initial treatment

Consider the following:

- It is important to differentiate between the possible diagnoses to determine the urgency of referral. Endophthalmitis requires immediate phone referral, as do most corneal conditions.
- Iritis can be a difficult diagnosis to make, so it is best to refer early.

Section communication checklist

Consider the following:

- ☒ Onset and duration of symptoms
- ☒ Painful/not painful
- ☒ Distribution of redness (localised or diffuse/involving tarsal conjunctiva)
- ☒ Purely unilateral or some contralateral symptoms
- ☒ Best (pinhole) visual acuity of each eye
- ☒ Eyelids involvement (red or swollen)
- ☒ Cornea normal or not normal, i.e. cloudy, opacities or fluorescein staining
- ☒ Anterior chamber normal or not normal, i.e. deep, presence of anterior chamber cells, blood or hypopyon
- ☒ Iris normal, i.e. round, equal, reactive pupils with normal iris detail visible
- ☒ Equal red reflexes

Specific communication checklist

Consider the following:

- ☒ Recent intraocular surgery, (e.g. cataract, injections)
- ☒ History of autoimmune disease
- ☒ Contralateral symptoms or a purely unilateral process
- ☒ Visual acuity
- ☒ Presence of hypopyon
- ☒ Anterior chamber cells can be seen on slit lamp
- ☒ Cornea appears normal

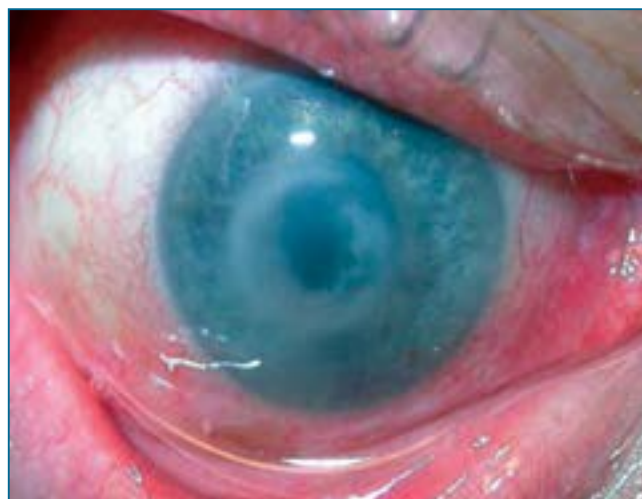Bacterial or acanthamoebal ulcer

Seek an urgent referral to an ophthalmologist.
Seek an immediate consultation by phone.



May require admission for microbiological investigation and intensive antibiotic treatment.

Figure 57. Bacterial ulcer.



History findings

- Often a history of contact lens wear

Specific communication checklist

Consider the following:

- ☒ History of contact lens wear and poor lens hygiene

Notes

- Epithelial defect with an opacified base

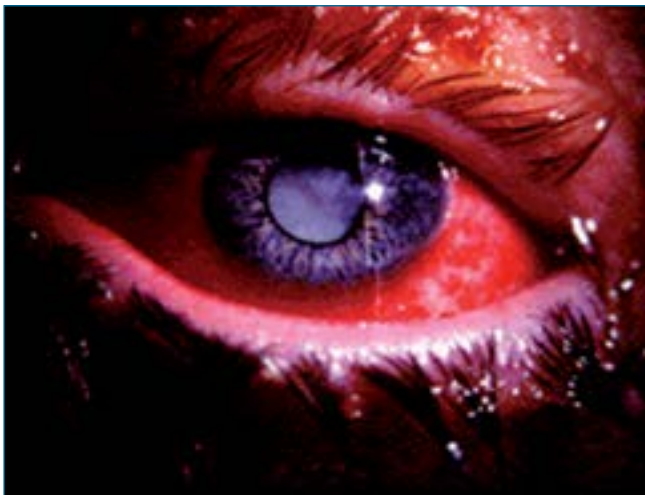Bacterial conjunctivitis

Referral is required if:

- vision is affected
- the condition does not improve with treatment after 2 days, or worsens
- the condition persists after 5 days of treatment.

Ophthalmia neonatorum, defined as conjunctivitis within the first 30 days of life, requires immediate specialist input and treatment. It should be considered a separate entity from the bacterial conjunctivitis that affects older children and adults.

Figure 58. Bacterial conjunctivitis. Tender inflamed conjunctiva with purulent discharge from the conjunctival sac.



History findings

Consider the following:

- Bacterial conjunctivitis features no corneal or anterior chamber involvement unless gonococcal conjunctivitis is suspected.
- It is essential to administer fluorescein to exclude corneal ulcers.
- A patient with bacterial conjunctivitis presents systemically well. The condition is common in the elderly and children.

Initial treatment

- Regular hygiene to minimise secretion buildup
- Wash hands and use separate tissues to avoid infection of the other eye or other people
- Topical antibiotics qid for 5 days

Notes

Non-gonococcal bacterial conjunctivitis presents with bulbar conjunctival injection and purulent or mucopurulent discharge.

Gonococcal bacterial conjunctivitis has marked bulbar conjunctival and periocular erythema and oedema.

It is important to exclude corneal infiltrate or ulcers that can lead to a sight-threatening perforation, usually superiorly.

Section communication checklist

Consider the following:

- ☒ Onset and duration of symptoms
- ☒ Painful/not painful
- ☒ Distribution of redness (localised or diffuse/involving tarsal conjunctiva)
- ☒ Purely unilateral, or some contralateral symptoms
- ☒ Best (pinhole) visual acuity of each eye
- ☒ Eyelids involvement (red or swollen)
- ☒ Cornea normal or not normal, i.e. cloudy, opacities or fluorescein staining
- ☒ Anterior chamber normal or not normal, i.e. deep, presence of anterior chamber cells, blood or hypopyon
- ☒ Iris normal, i.e. round, equal, reactive pupils with normal iris detail visible
- ☒ Equal red reflexes

Chalazion/stye

A chalazion swelling is due to a blocked sebaceous gland. The lid margin is not involved unless a secondary infection occurs.

A stye is an acute bacterial infection close to/ involving the lid margin. It is associated with lash follicles and is painful.

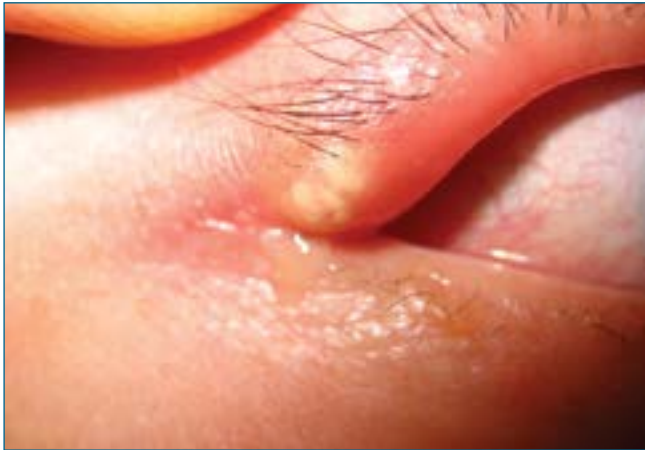
Figure 59. Chalazion as seen from the tarsal conjunctival side.

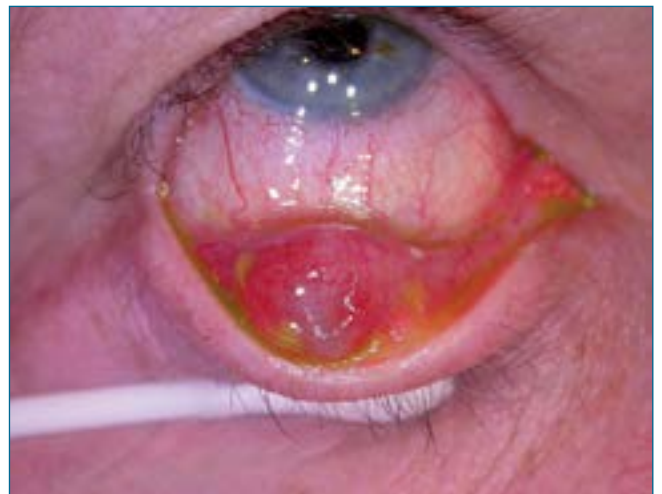

Figure 60. Chalazion in the upper eyelid, seen from the skin side.¹⁶

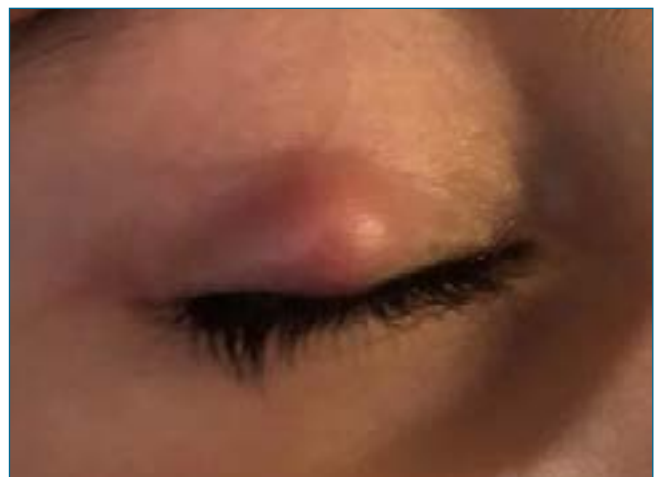

Figure 61. Stye in the upper eyelid, at the outer canthus.



Initial treatment

Consider the following:

- Eyelid hygiene: the eyelid lump will often disappear after several months of eyelid hygiene. If bothersome, it may instead be incised by an ophthalmologist.
- If acutely inflamed with surrounding eyelid inflammation, treat as for preseptal cellulitis with oral antibiotics (dosage as per preseptal cellulitis) and warm compresses (twice daily) and ensure ophthalmology follow-up.

Important differentials

Other eyelid lumps, including squamous cell carcinoma or basal cell carcinoma.

Section communication checklist

Consider the following:

- ☒ Onset and duration of symptoms
- ☒ Painful/not painful
- ☒ Distribution of redness (localised or diffuse/involving tarsal conjunctiva)
- ☒ Purely unilateral, or some contralateral symptoms
- ☒ Best (pinhole) visual acuity of each eye
- ☒ Eyelids involvement (red or swollen)
- ☒ Cornea normal or not normal, i.e. cloudy, opacities or fluorescein staining
- ☒ Anterior chamber normal or not normal, i.e. deep, presence of anterior chamber cells, blood or hypopyon
- ☒ Iris normal, i.e. round, equal, reactive pupils with normal iris detail visible
- ☒ Equal red reflexes

Corneal or conjunctival foreign body/corneal abrasion

Consider the following:



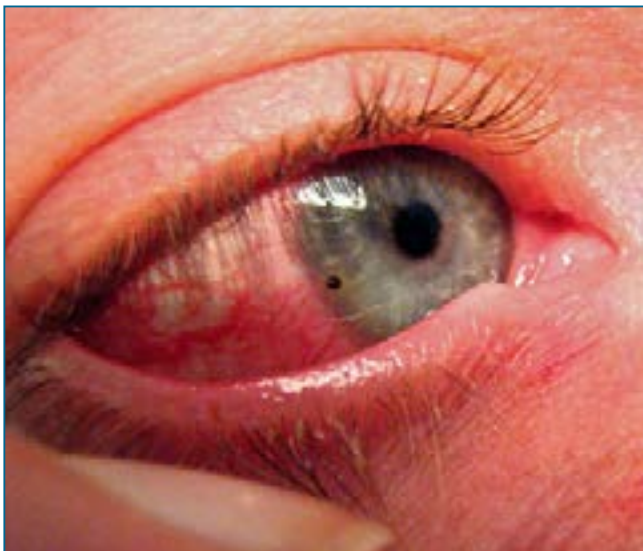- Exclude a penetrating eye injury.
- Any foreign body penetration of the cornea or retained foreign body requires an urgent referral to an ophthalmologist for immediate consultation by phone.
- Discuss with senior staff if the foreign body is centrally located on the cornea (over the visual axis).

History findings

Consider:

- what material the foreign body likely consists of, e.g. dirt, glass, metal or organic
- the mechanism of impact (hitting metal on metal is highly likely to cause a penetrating injury, whereas grinding or welding rarely do so).

Figure 62. A small piece of iron has lodged in the corneal periphery. Some rust can already be seen.¹⁷



Examination findings

1. Visual acuity: if not 6/6 then check with a pinhole.
2. Slit lamp: assess for the size, site/s and nature of foreign body and the depth of penetration.
3. Examine the cornea, anterior chamber, iris, pupil and lens for any distortion that may indicate ocular penetration and require urgent referral to an ophthalmologist.
4. Evert the eyelids to exclude retained subtarsal foreign bodies and remove them if appropriate.
5. Use fluorescein to exclude Seidel-positive corneal perforation and measure the size of the epithelial defect.

Important differentials

Penetrating eye injury: partial thickness corneal lacerations or full thickness corneal perforations.

Initial treatment

Instruments

- Gloves
- Cotton bud (see Figure 63)
- 21–25g needle (see Figure 65)
- Optional: motorised dental burr (see Figure 64)

Bend the needle tip to 45° from the shaft. Use the bevelled surface of the instrument angled away from the patient's eye. The patient's forehead should rest against the slit lamp (see Figure 66).

A motorised dental burr is ONLY for use outside the central 5mm of the cornea. Always obtain supervision if you are unfamiliar with the procedure.

Figure 63. Eye drops, cotton bud and 21-25g needle.

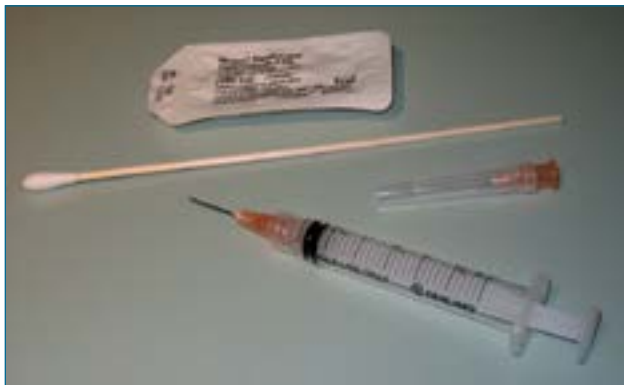

Figure 64. Motorised dental burr.



Procedure

1. Apply topical anaesthetic agents such as Amethocaine 1%. Repeat every 30 seconds until no further discomfort on instillation.
2. Position the patient at slit lamp. Strap or hold the patient's head with the help of a colleague and ask the patient to focus on your ear.
3. Focus the slit lamp.
4. Use an oblique approach tangential to the cornea. This is very important to reduce the risk of corneal perforation (see Figure 65 and Figure 66).
5. Angling a narrow slit beam to 45° can help identify the depth of the foreign body and ensure the safety of further removal attempts.

Figure 65. 25G needle angled away from the patient.

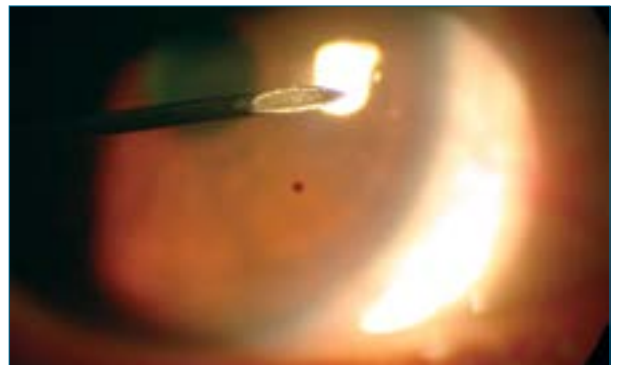
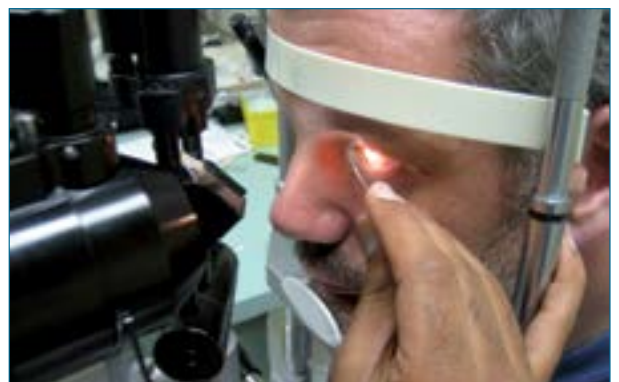

Figure 66. Corneal foreign body removal with 25G needle.



After removal

Consider the following:

- Use topical antibiotic (qid) and a cycloplegic agent, (e.g. cyclopentolate 1% bd) for comfort. Drops are often preferred and are equally as effective as an ointment in healing a corneal wound. Administer oral analgesia as required.
- It is not necessary to pad an eye. The advantage of not padding is that the patient can see with both eyes.
- The continued use of anaesthetic drops is contraindicated.
- Assess daily visual acuity and slit lamp review until complete healing of the defect. The defect should be measured (see the section on slit lamp examination) and compared with previous findings.

Specific communication checklist

Consider the following:

- ☒ Mechanism and likely type of foreign body
- ☒ Location of the foreign body on the cornea
- ☒ Presence of a residual foreign body or rust ring

Notes

- Visual acuity may be reduced in a simple corneal foreign body due to patient discomfort or refractive errors. Administer topical local anaesthetic, (e.g. Amethocaine), darken the room and repeat using a pinhole.
- Retained organic material may lead to infection; retained metallic foreign bodies may lead to the formation of rust rings that produce scarring and corneal epithelial defects.
- Rust rings in the visual axis should be removed by an ophthalmologist or suitably experienced emergency physician.
- Protective eyewear is useful but does not exclude an open globe injury.

Figure 67. Corneal foreign body (macro).

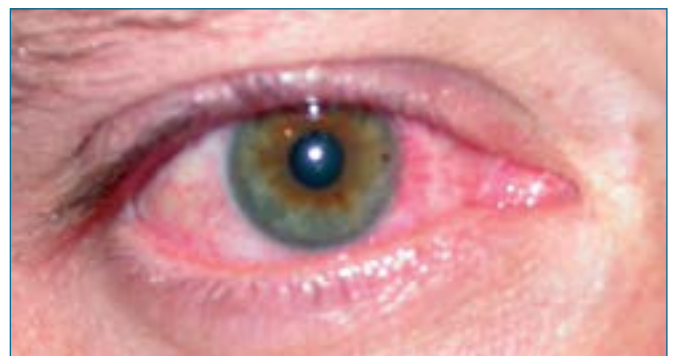
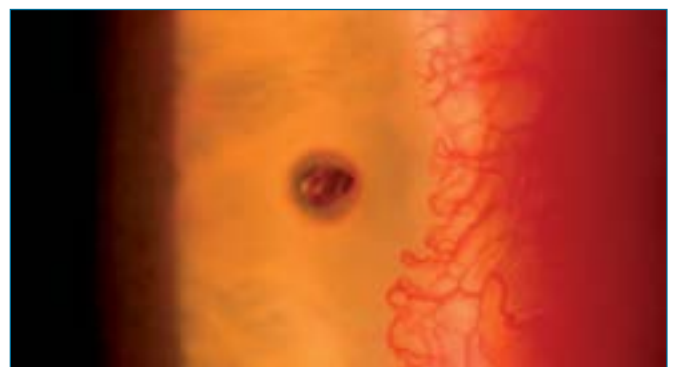

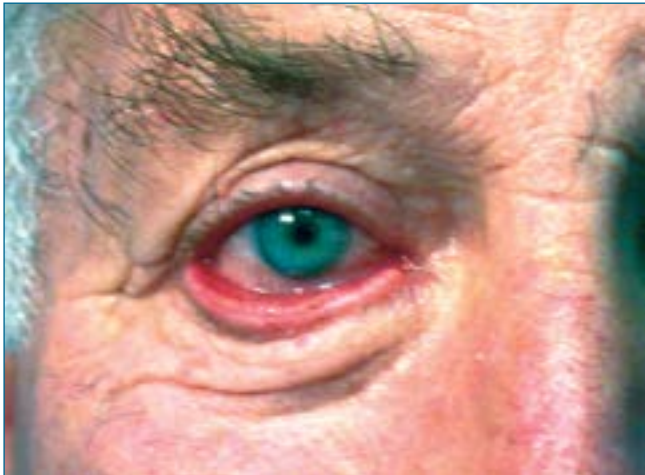
Figure 68. Corneal foreign body (micro). A small piece of iron has lodged near the margin of the cornea. Some rust can already be seen.



Ectropion

Ectropion is a lower eyelid turning outwards with exposure of the tarsal conjunctiva. It is usually age-related but may be caused by Bell's palsy or contracting scars on the skin of the lower eyelid and cheek.

Figure 69. Ectropion.



Examination findings

Consider the following:

- The lower eyelid is loose and can easily be pulled millimetres from the globe. The tarsal conjunctiva faces outward and often appears red due to chronic exposure.
- The eye itself is white. Slit lamp examination with fluorescein may reveal some inferior punctate erosions due to chronic exposure of the inferior cornea and conjunctiva.
- The visual acuity is usually normal.

Initial treatment

- Topical lubrication, including night-time ointment
- Refer to an ophthalmologist for non-urgent surgical management

Section communication checklist

Consider the following:

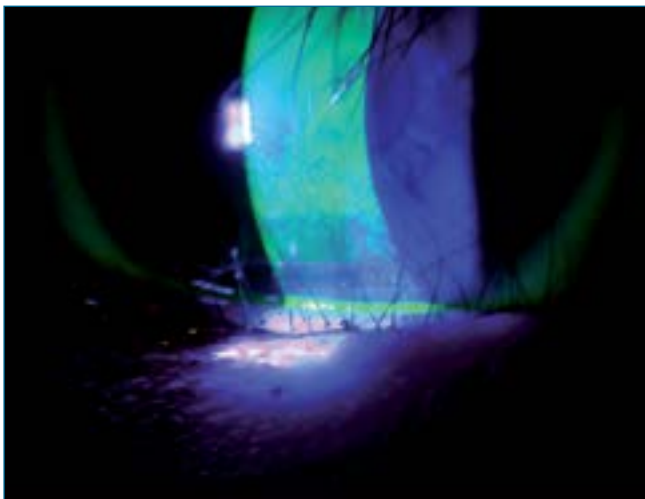
- ☒ Onset and duration of symptoms
- ☒ Painful/not painful
- ☒ Distribution of redness (localised or diffuse/involving tarsal conjunctiva)
- ☒ Purely unilateral, or some contralateral symptoms
- ☒ Best (pinhole) visual acuity of each eye
- ☒ Eyelids involvement (red or swollen)
- ☒ Cornea normal or not normal, i.e. cloudy, opacities or fluorescein staining
- ☒ Anterior chamber normal or not normal, i.e. deep, presence of anterior chamber cells, blood or hypopyon
- ☒ Iris normal, i.e. round, equal, reactive pupils with normal iris detail visible
- ☒ Equal red reflexes

Entropion

Figure 70. Entropion.

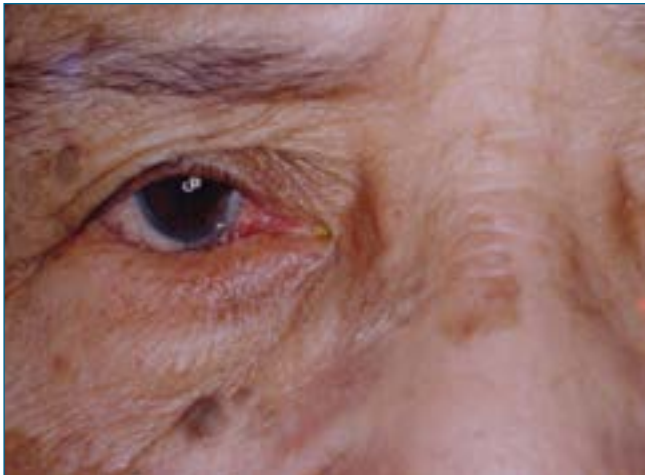

Figure 71. Corneal abrasion.



History findings

- Ocular irritation, foreign body sensation or tearing

Examination findings

Check the condition of the cornea with a slit lamp and under blue light with fluorescein:

- an intact cornea requires lubrication with a non-urgent referral

- a corneal ulcer requires taping back the eyelid away from the cornea, management as for a corneal foreign body and an ophthalmology follow-up
- a corneal infection (corneal white opacity and ulcer) requires urgent referral to an ophthalmologist.

Notes

Entropion may be age-related, or due to conjunctival scarring from previous chemical injury, trauma, surgery or systemic conditions such as Stevens-Johnson syndrome. Surgery may be required to reposition the eyelid.

Section communication checklist

Consider the following:

- ☒ Onset and duration of symptoms
- ☒ Painful/not painful
- ☒ Distribution of redness (localised or diffuse/involving tarsal conjunctiva)
- ☒ Purely unilateral, or some contralateral symptoms
- ☒ Best (pinhole) visual acuity of each eye
- ☒ Eyelids involvement (red or swollen)
- ☒ Cornea normal or not normal, i.e. cloudy, opacities or fluorescein staining
- ☒ Anterior chamber normal or not normal, i.e. deep, presence of anterior chamber cells, blood or hypopyon
- ☒ Iris normal, i.e. round, equal, reactive pupils with normal iris detail visible
- ☒ Equal red reflexes

Episcleritis

Episcleritis is the inflammation of the connective tissue overlying the sclera.

History findings

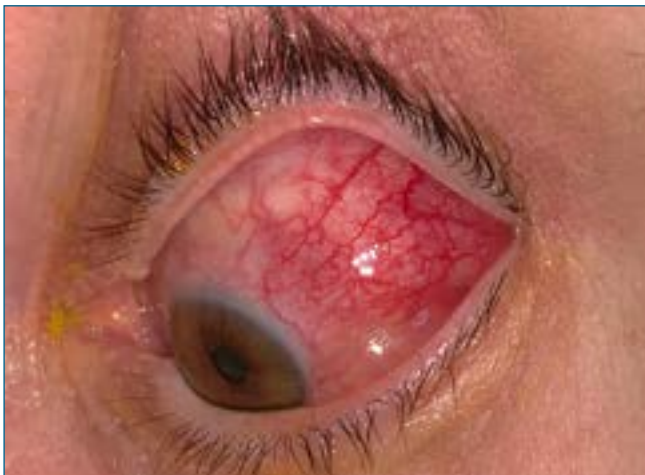- Acute onset redness and discomfort, usually focal
- May be unilateral or bilateral
- Vision is unaffected

Important differentials

Consider the following:

- Scleritis: pain wakes the patient from sleep and the globe is tender to gentle pressure through the closed eyelid
- Conjunctivitis: redness tends to be more generalised and the tarsal conjunctiva (evert the lower eyelid) is involved
- Pterygium (when inflamed): raised nasal pterygium, with localised redness, possibly with some punctate conjunctival staining with fluorescein

Figure 72. Episcleritis of the eyeball.¹⁸



Initial treatment

- Try frequent (hourly) preservative-free lubricating drops or gels/ointments
- Minimise exposure to sun, wind and air-conditioning
- Oral NSAIDs may be helpful
- Non-urgent referral to an ophthalmologist if recurrent or concerns regarding possible scleritis

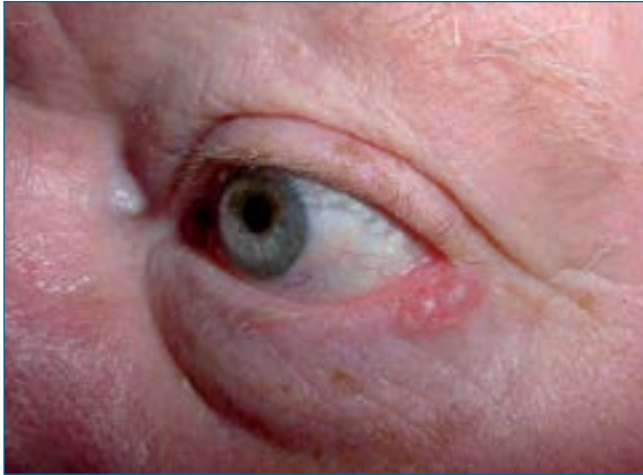
Section communication checklist

Consider the following:

- ☒ Onset and duration of symptoms
- ☒ Painful/not painful
- ☒ Distribution of redness (localised or diffuse/involving tarsal conjunctiva)
- ☒ Purely unilateral, or some contralateral symptoms
- ☒ Best (pinhole) visual acuity of each eye
- ☒ Eyelids involvement (red or swollen)
- ☒ Cornea normal or not normal, i.e. cloudy, opacities or fluorescein staining
- ☒ Anterior chamber normal or not normal, i.e. deep, presence of anterior chamber cells, blood or hypopyon
- ☒ Iris normal, i.e. round, equal, reactive pupils with normal iris detail visible
- ☒ Equal red reflexes

Eyelid lesion

Figure 73. Lesion of left lower eyelid.



Initial treatment

Provided there is no overt eyelid infection/ inflammation and no ocular involvement, non-urgent referral is required. Consider topical antibiotics.

Herpes simplex virus keratitis (HSV/HSK)



- Herpetic blepharoconjunctivitis
- Ophthalmia neonatorum

Figure 74. Herpes simplex keratitis.

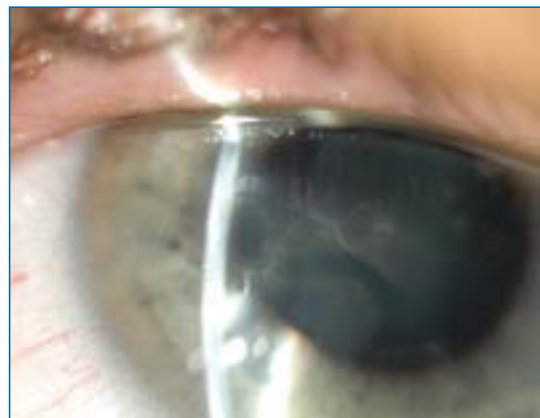

Figure 75. Herpes simplex keratitis dendritic ulcer with terminal bulbs.

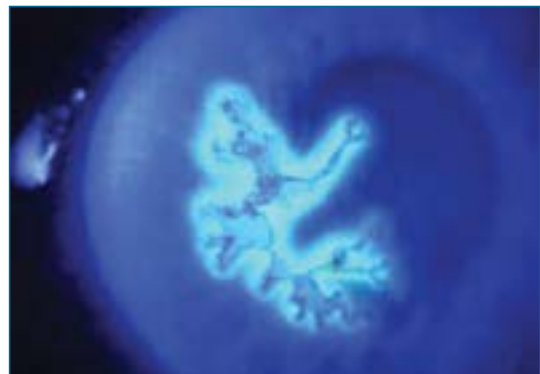
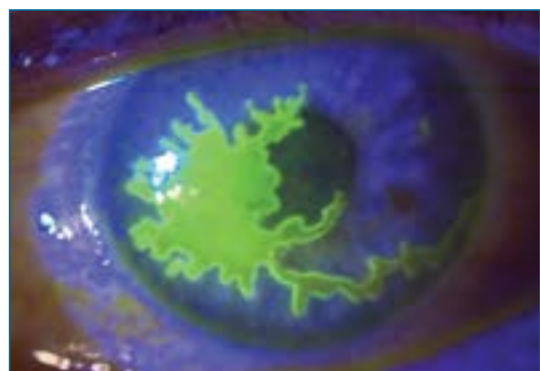


Figure 76. Herpes simplex keratitis with steroid complication.



History findings

- Unilateral red eye
- Mild blurring of vision
- May have a history of similar episodes in the same eye or of cold sores
- Ask about possible systemic immunosuppression
- Topical steroid use will significantly worsen this condition

Examination findings

Consider the following:

- Use fluorescein to ascertain the nature of any epithelial defect.
- Check for dendritic ulcer/s, which are usually unilateral.
- Multiple previous episodes may have also led to cornea stromal scarring and decreased vision.
- A dendritic ulcer (affecting the corneal epithelium) may also be complicated by inflammation of the deeper corneal layers, which, if left untreated, can sometimes lead to perforation. Look for corneal opacification, loss of iris detail through a cloudy cornea and reduced vision.

Initial treatment

- Treat with topical acyclovir
- Avoid topical steroid
- Refer to an ophthalmologist within 1–2 days

Specific communication checklist

Consider the following:

- ☒ History of cold sores
- ☒ Onset and duration of symptoms
- ☒ Painful/not painful
- ☒ Distribution of redness (localised or diffuse/ involving tarsal conjunctiva)
- ☒ Purely unilateral, or some contralateral symptoms
- ☒ Best (pinhole) visual acuity of each eye
- ☒ Eyelids involvement (red or swollen)
- ☒ Cornea normal or not normal, i.e. cloudy, opacities or fluorescein staining
- ☒ Anterior chamber normal or not normal, i.e. deep, presence of anterior chamber cells, blood or hypopyon
- ☒ Iris normal, i.e. round, equal, reactive pupils with normal iris detail visible
- ☒ Equal red reflexes

Notes

- Stain with fluorescein as the cornea may develop microdendrites or ulceration.
- Atopic patients will often have more severe disease.
- Children may develop blepharoconjunctivitis in primary herpes simplex infection. It may be bilateral or unilateral, with periocular vesicles or conjunctivitis.
- Herpes simplex virus keratitis may also be associated with eczema in children.
- Children will often require admission and systemic antivirals.
- See the section on ophthalmia neonatorum if HSV ocular disease in the first month of life is suspected.

Herpes zoster ophthalmicus (HZO)/shingles

Seek an urgent referral to an ophthalmologist. Contact an ophthalmologist on the same day if ocular involvement is suspected.

Figure 77. Herpes zoster.

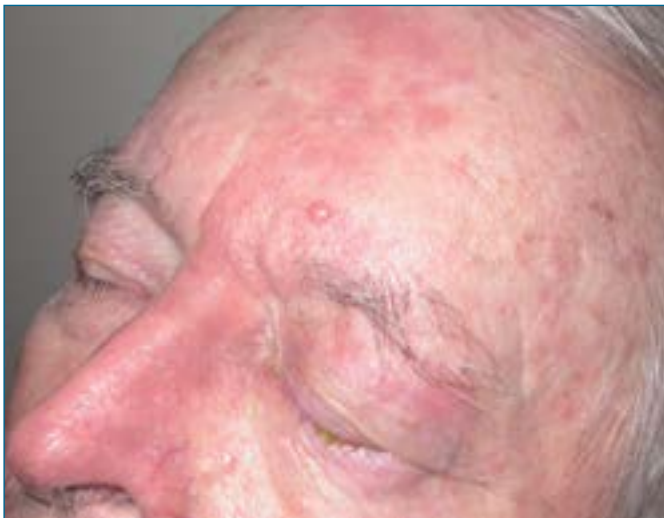
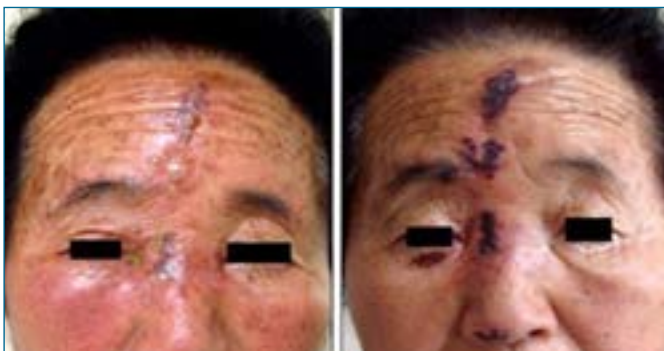
Figure 78. Erythema, oedema, vesiculobullous eruptions and crusted erosions were present on the right side of the forehead and yellowish lacrimation was noted from the right orbital area in the first image. Second image shows improvement after 7 days of treatment. Note the vesicles and crusts on the top and side of the nose (Hutchinson's sign).¹⁹



Herpes zoster ophthalmicus is shingles affecting the ophthalmic branch of the trigeminal nerve (V1). It may or may not involve the eye, which also has sensory innervation from V1.

History findings

- Unilateral vesicles over the forehead, scalp and eyelid
- Often associated with severe pain
- Ask about systemic immunosuppression, (e.g. drugs, HIV and cancer)

Examination findings

Consider the following:

- Check visual acuity, extraocular movements, intraocular pressure and pupils, including checking for relative afferent pupillary defect (RAPD).
- A general inspection will reveal a vesicular rash, which is usually unilateral and does not cross the midline. Lesions will crust after a few days.
- Ocular findings may include blepharitis (lid vesicle and redness), conjunctivitis, corneal ulcers (pseudodendrites), viral keratitis (corneal opacities or clouding and oedema), signs of iritis, retinitis and optic disc swelling.

Initial treatment

Oral antivirals should ideally be commenced within 72 hours of the appearance of the rash.

Notes

- If the tip of the nose is involved (Hutchinson's sign), there is a higher risk of ocular involvement.
- Always suspect ocular involvement if the eye is red, vision is reduced or fluorescein staining is present.
- Ocular involvement should prompt ophthalmic referral within 24 hours, or earlier if the vision is affected or there are abnormalities on fundoscopy.

Section communication checklist

Consider the following:

- ☒ History of cold sores often exists
- ☒ Onset and duration of symptoms
- ☒ Painful/not painful
- ☒ Distribution of redness (localised or diffuse/involving tarsal conjunctiva)
- ☒ Purely unilateral, or some contralateral symptoms
- ☒ Best (pinhole) visual acuity of each eye
- ☒ Eyelids involvement (red or swollen)
- ☒ Cornea normal or not normal, i.e. cloudy, opacities or fluorescein staining
- ☒ Anterior chamber normal or not normal, i.e. deep, presence of anterior chamber cells, blood or hypopyon
- ☒ Iris normal, i.e. round, equal, reactive pupils with normal iris detail visible
- ☒ Equal red reflexes

Hyphaema

Seek urgent ophthalmology referral and immediate consultation by phone.

Hyphaema is the presence of blood in the anterior chamber. It may present as a fine suspension of red blood cells in aqueous (micro-hyphaema) or as a blood-aqueous fluid level (macro-hyphaema) as shown in Figure 79 and Figure 80).

Figure 79. Hyphaema.

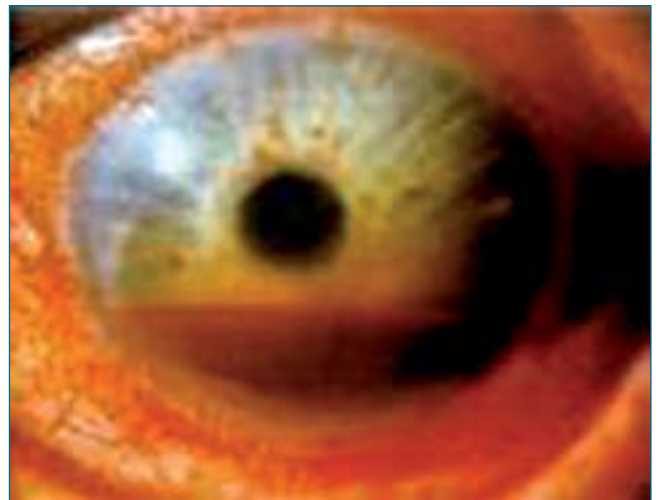
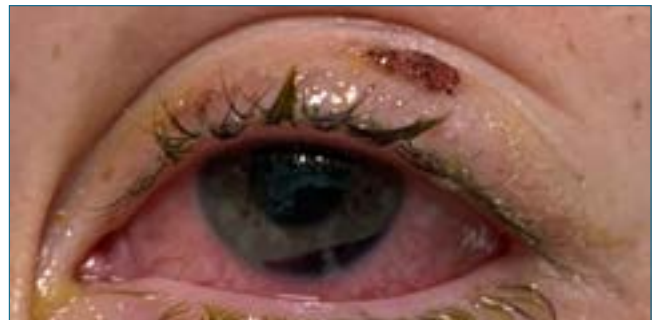

Figure 80. A 2mm macro-hyphaema, as measured from the inferior limbus. Note the pupil is dilated inferiorly. This may signify a focal traumatic mydriasis, which is often present in a blunt (closed-eye) injury.



Photograph courtesy of Lawrence B. Stack, MD, Professor of Emergency Medicine and Paediatrics, Vanderbilt University Medical Center, Nashville, Tennessee, USA.

History findings

- Usually trauma-related
- Consider non-accidental injury in children and blood dyscrasias

Examination findings

- Check visual acuity and pupils
- Check intraocular pressure as this is often acutely elevated
- Check for other evidence of blunt eye injury and orbital fracture

Initial treatment

- Protect the eye with a shield
- Avoid pressure on the eye
- Bed rest

Section communication checklist

Consider the following:

- ☒ Onset and duration of symptoms
- ☒ Painful/not painful
- ☒ Distribution of redness (localised or diffuse/involving tarsal conjunctiva)
- ☒ Purely unilateral, or some contralateral symptoms
- ☒ Best (pinhole) visual acuity of each eye
- ☒ Eyelids involvement (red or swollen)
- ☒ Cornea normal or not normal, i.e. cloudy, opacities or fluorescein staining
- ☒ Anterior chamber normal or not normal, i.e. deep, presence of anterior chamber cells, blood or hypopyon
- ☒ Iris normal, i.e. round, equal, reactive pupils with normal iris detail visible
- ☒ Equal red reflexes

Notes

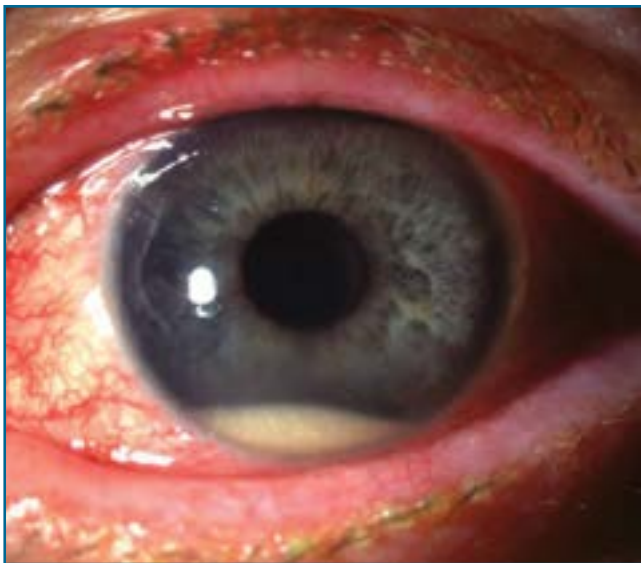
- Permanent vision loss may be caused by elevated intraocular pressure, cornea blood staining with prolonged hyphaemia and associated ocular blunt eye injuries, (e.g. retinal detachment).

Hypopyon

Seek urgent ophthalmology referral and immediate consultation by phone.

Hypopyon is the presence of pus in the anterior chamber. It is a sinister sign and is usually associated with florid intraocular infection (endophthalmitis), requiring immediate referral to an ophthalmologist.

Figure 81. Hypopyon with a visible accumulation of white cells inferiorly seen in severe uveitis.



History findings

- History of intraocular injection, cataract, glaucoma or other ocular surgery
- History of eye trauma, intraocular foreign body or contact lens wear
- Pain, redness or blurring/loss of vision
- Current eyedrops used

Examination findings

- Visual acuity and pupils
- Slit lamp examination looking for a leaking open wound (Seidel's test)
- Check intraocular pressure

Section communication checklist

Consider the following:

- ☒ Onset and duration of symptoms
- ☒ Painful/not painful
- ☒ Distribution of redness (localised or diffuse/involving tarsal conjunctiva)
- ☒ Purely unilateral, or some contralateral symptoms
- ☒ Best (pinhole) visual acuity of each eye
- ☒ Eyelid involvement (red or swollen)
- ☒ Cornea normal or not normal, i.e. cloudy, opacities or fluorescein staining
- ☒ Anterior chamber normal or not normal, i.e. deep, presence of anterior chamber cells, blood or hypopyon
- ☒ Iris normal, i.e. round, equal, reactive pupils with normal iris detail visible
- ☒ Equal red reflexes

Specific communication checklist

Consider the following:

- ☒ Recent ocular surgery or trauma

Notes

Hypopyon is a sign that there is severe anterior chamber inflammation. This may be due to endophthalmitis, a severe corneal infection, or florid uveitis. It should be urgently managed as endophthalmitis until proven otherwise.

Intravitreal injection (for macular degeneration) or cataract surgery in the past 1–2 weeks accounts for most cases of endophthalmitis.

Treatment is immediate intravitreal antibiotics administered by the ophthalmologist. Failure to institute prompt treatment often leads to permanent loss of vision or the eye.

Marginal keratitis

Seek immediate referral to an ophthalmologist.

Figure 82. Marginal keratitis.

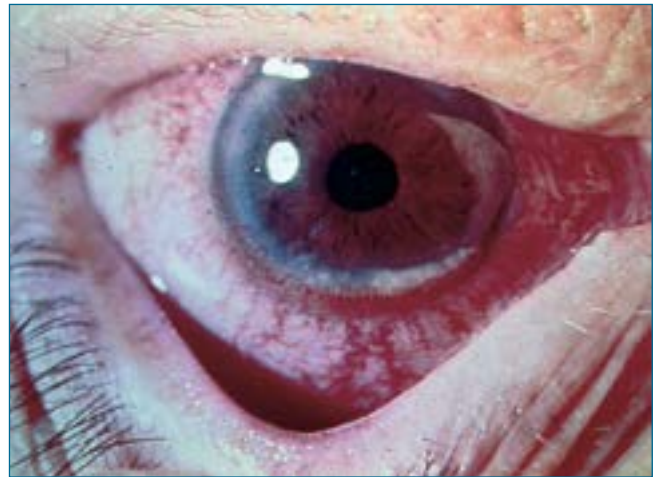
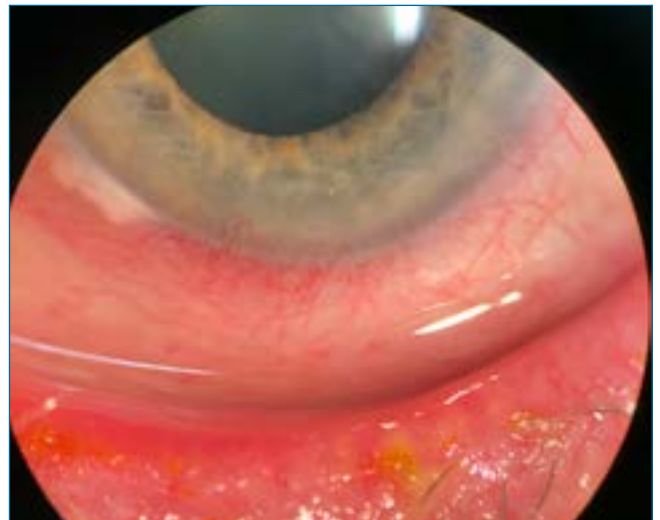

Figure 83. Slit lamp photograph of the right eye with marginal keratitis between 12 o'clock to 2 o'clock positions along with a pannus.²⁰



Notes

Marginal keratitis:

- is secondary to blepharitis
- features ulcers situated at the corneal periphery
- requires discussion with an ophthalmologist.

Neovascular glaucoma

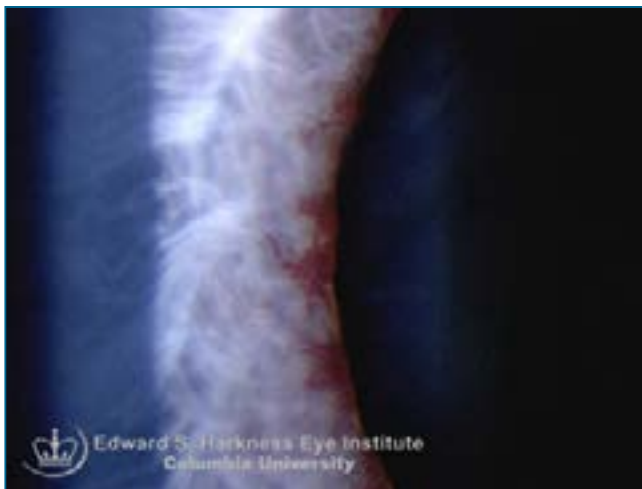
Seek an urgent referral to an ophthalmologist (<24hr).

Neovascular glaucoma is a type of glaucoma that is caused by vascular injury to the eye, including diabetic retinopathy, central retinal vein occlusion, central retinal artery occlusion and ocular ischaemic syndrome. The intraocular pressure is often >35mmHg, and it is a difficult condition to treat.



Poor vision and high intraocular pressure (cloudy cornea, nausea or vomiting).

Figure 84. Tufts of neovascularisation at the peripupillary margin.²¹



History findings

Pain, red eye, photophobia and reduced vision. May have a history of sudden and persistent visual loss and/or multiple cardiovascular risk factors.

Examination findings

- Vision may be reduced due to the underlying cause of ocular ischaemia
- Iris neovascularisation and conjunctival erythema
- Cloudy cornea if intraocular pressure is raised
- Pupils may be fixed, dilated or show an RAPD
- Fundus examination may show retinal pathology resulting in ischaemia, e.g. diabetic retinopathy or central retinal vein occlusion (CRVO)

Investigations

- Cardiovascular risk factor work up

Important differentials

- Acute angle closure or uveitic glaucoma

Initial treatment

- Consult the ophthalmology team to establish a diagnosis and underlying cause
- Address cardiovascular risk factors

Section communication checklist

Consider the following:

- ☒ Onset and duration of symptoms
- ☒ Painful/not painful
- ☒ Distribution of redness (localised or diffuse/involving tarsal conjunctiva)
- ☒ Purely unilateral, or some contralateral symptoms
- ☒ Best (pinhole) visual acuity of each eye
- ☒ Eyelids involvement (red or swollen)
- ☒ Cornea normal or not normal, i.e. cloudy, opacities or fluorescein staining
- ☒ Anterior chamber normal or not normal, i.e. deep, presence of anterior chamber cells, blood or hypopyon
- ☒ Iris normal, i.e. round, equal, reactive pupils with normal iris detail visible
- ☒ Equal red reflexes

Specific communication checklist

Consider the following:

- ☒ Medical history and ocular history
- ☒ Cardiovascular risk factors
- ☒ Visual acuity, pupil assessment, anterior segment findings and intraocular pressure if able to obtain

Ophthalmia neonatorum (neonatal conjunctivitis)

Seek an urgent referral to an ophthalmologist, paediatrician and infectious diseases specialist. This condition often requires admission to hospital for investigation and treatment.

Ophthalmia neonatorum is an acute purulent conjunctival infection in the first weeks of life. Organisms of concern include *Neisseria gonorrhoeae* (*N.gonorrhoeae*) (especially within the first 5 days), *Chlamydia trachomatis* (*C. trachomatis*) (up to 60 days) or HSV. Scarring or perforation can occur and any signs of gonococcal sepsis should be elicited. Gonococcal ophthalmia presents with florid swelling. Chlamydial ophthalmia usually presents with milder chemosis. HSV is seen within 2 weeks after birth and may have typical vesicles on the eyelid margin. Exclude corneal dendrite with fluorescein staining.



Ophthalmia neonatorum is a serious infection due to the lack of immunity in the neonate. Systemic complications include meningitis, sepsis, arthritis and pneumonia.

Sight-threatening ocular complications include corneal ulcer and perforation.

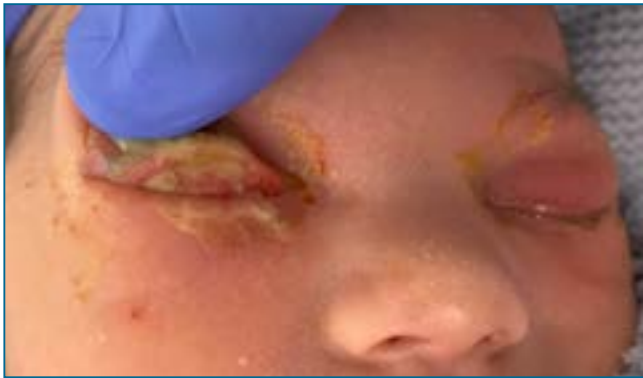
History findings

- Previous or current sexually transmitted maternal infection
- Vaginal delivery
- Occurs in the first month of life

Examination findings

- Bilateral mucopurulent discharge typically
- Red eyes and diffuse conjunctival injection
- Perform fluorescein staining to exclude corneal ulcers or dendrites

Figure 85. Newborn with gonococcal ophthalmia neonatorum caused by a maternally transmitted gonococcal infection.²²



Investigations

- Swab for urgent microscopy and culture
- Consider blood cultures to exclude sepsis or gonococcal infection concerns

Important differentials

Consider the following:

- Dacryocystitis presents with swelling and erythema just below the inner canthus, but the eye appears white.
- Nasolacrimal duct obstruction involves high tear film and reflux of mucopurulent material from the punctum when pressure is applied over the lacrimal sac. The eye is white. Symptoms usually appear in the first 1–2 months of life.

Initial treatment

- Urgent systemic and topical antibiotic treatment
- Referral to a sexual health clinic for treatment of parents and contact tracing

Specific communication checklist

Consider the following:

- ☒ Ask parents about sexually transmitted infections

Section communication checklist

Consider the following:

- ☒ Onset and duration of symptoms
- ☒ Painful/not painful
- ☒ Distribution of redness (localised or diffuse/involving tarsal conjunctiva)
- ☒ Purely unilateral, or some contralateral symptoms
- ☒ Best (pinhole) visual acuity of each eye
- ☒ Eyelid involvement (red or swollen)
- ☒ Cornea normal or not normal, i.e. cloudy, opacities or fluorescein staining
- ☒ Anterior chamber normal or not normal, i.e. deep, presence of anterior chamber cells, blood or hypopyon
- ☒ Iris normal, i.e. round, equal, reactive pupils with normal iris detail visible
- ☒ Equal red reflexes

Notes

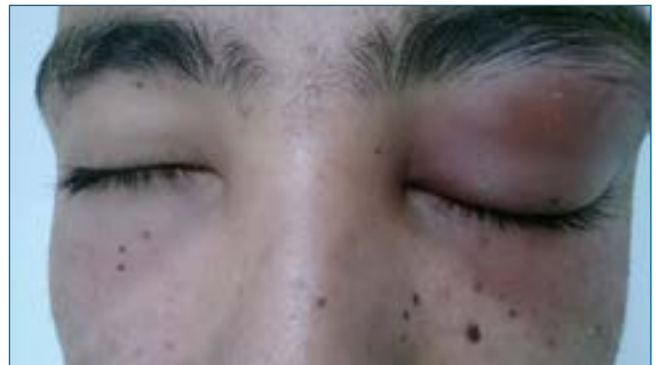Consider the following:

- As a notifiable disease, parents must be investigated and treated. Seek a referral to a sexual health clinic.
- Causes include gonorrhoea, chlamydia or HSV infections.
- A gonorrhoeal infection is usually seen within 3–4 days after birth, with severe chemosis and copious discharge. Urgent systemic treatment is required, as delays may lead to corneal perforation.
- Chlamydia is the most common causative infection and is usually seen within the first week after birth with mild swelling and chemosis.
- HSV is seen within 2 weeks after birth and may present as typical vesicles on the eyelid margin. Exclude corneal dendrite with fluorescein staining.

Preseptal cellulitis (periorbital cellulitis)

Seek an urgent referral to an ophthalmologist (<24 hours).

Figure 86. Periorbital cellulitis in a 20-year-old man.²³



History findings

- Trivial trauma may precede cellulitis, including an insect bite, chalazion or skin trauma

Examination findings

- Check for proptosis (should be absent but do not confuse with lid swelling) and extraocular movements (should be normal)
- Visual acuity and optic nerve function testing should be normal
- The eye should appear white
- Usually features unilateral eyelid erythema, tenderness and warmth
- Usually features minimal conjunctival injection and no pain with eye movements

Important differentials

Consider the following:

- Orbital cellulitis: optic nerve function and vision may be affected, as well as ocular motility. Proptosis and painful eye movements may also occur.
- Chalazion: a blocked Meibomian gland may initially present with diffuse inflammation of the preseptal tissues. This often cannot be differentiated from preseptal cellulitis clinically and should therefore be treated as such. Within a few days, however, a distinct eyelid lump can be felt and seen, pointing to the diagnosis of chalazion.

Initial treatment

If the eye is unable to be visualised, or the child is febrile or unwell or less than 2 years old, then they must be urgently referred to exclude and treat possible orbital cellulitis.

Children older than 2 years with non-severe preseptal infection, who are afebrile and systemically well, may be treated with broad-spectrum oral antibiotics and daily review.

Seek a same day referral by phone to the ophthalmologist.

Section communication checklist

Consider the following:

- ☒ Onset and duration of symptoms
- ☒ Painful/not painful
- ☒ Distribution of redness (localised or diffuse/involving tarsal conjunctiva)
- ☒ Purely unilateral, or some contralateral symptoms
- ☒ Best (pinhole) visual acuity of each eye
- ☒ Eyelids involvement (red or swollen)
- ☒ Cornea normal or not normal, i.e. cloudy, opacities or fluorescein staining
- ☒ Anterior chamber normal or not normal, i.e. deep, presence of anterior chamber cells, blood or hypopyon
- ☒ Iris normal, i.e. round, equal, reactive pupils with normal iris detail visible
- ☒ Equal red reflexes

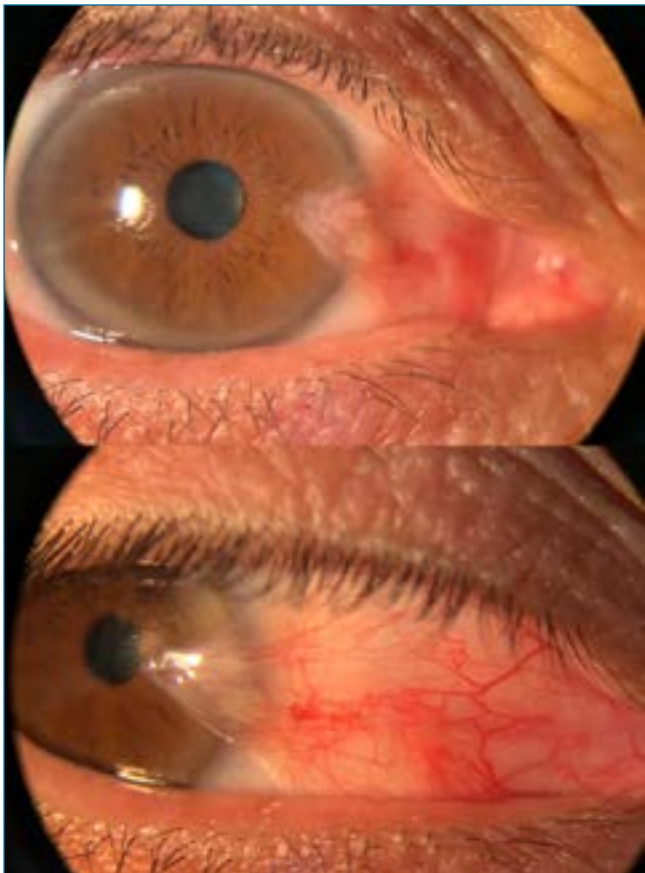
Specific communication checklist

Consider the following:

- ☒ History of recent viral URTI or sinus infection
- ☒ Ask for a history of recent skin infection or trauma

Pterygium

Figure 87. Right nasal pterygium. The eye is looking to the right.



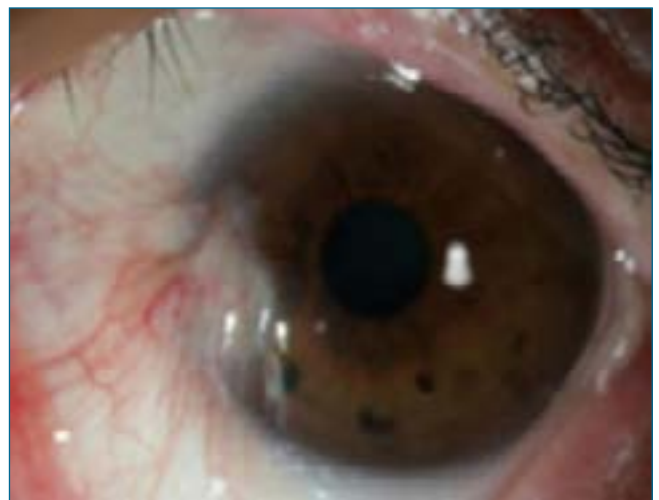
Pterygium is a raised, yellowish fleshy lesion at the limbus that may become painful and red if inflamed. It is usually on the nasal side and is often bilateral.

History findings

Consider the following:

- A white lesion, often there for many years, which occasionally becomes red and painful, particularly following prolonged exposure to dry air and wind, (e.g. long plane flights or air-conditioning). Once inflamed, it may require several days to settle.
- Check for a history of sun exposure or an outdoor occupation.

Figure 88. Anterior segment image of pterygium case. The surface vascularity is scored as +++.²⁴



Examination findings

Consider the following:

- Visual acuity may be decreased, but not acutely, as the presence of the pterygium can cause optical distortion (astigmatism). This can be somewhat corrected with glasses or a pinhole on testing.
- There may be mild punctate staining on fluorescein testing over the pterygium or adjacent cornea.

Important differentials

- Conjunctival dysplastic lesions look more fleshy, raised and vascular, and are often rapidly growing
- If in doubt, refer to the ophthalmologist

Initial treatment

- Lubricating eye drops hourly (preservative-free drops or gel)
- Wrap-around sunglasses when outdoors

Notes

- Pterygium typically has a long duration and affects the nasal conjunctivae more frequently.
- It may be surgically excised by an ophthalmologist if frequently inflamed or vision-threatening.

Section communication checklist

Consider the following:

- ☒ Onset and duration of symptoms
- ☒ Painful/not painful
- ☒ Distribution of redness (localised or diffuse/involving tarsal conjunctiva)
- ☒ Purely unilateral, or some contralateral symptoms
- ☒ Best (pinhole) visual acuity of each eye
- ☒ Eyelids involvement (red or swollen)
- ☒ Cornea normal or not normal, i.e. cloudy, opacities or fluorescein staining
- ☒ Anterior chamber normal or not normal, i.e. deep, presence of anterior chamber cells, blood or hypopyon
- ☒ Iris normal, i.e. round, equal, reactive pupils with normal iris detail visible
- ☒ Equal red reflexes

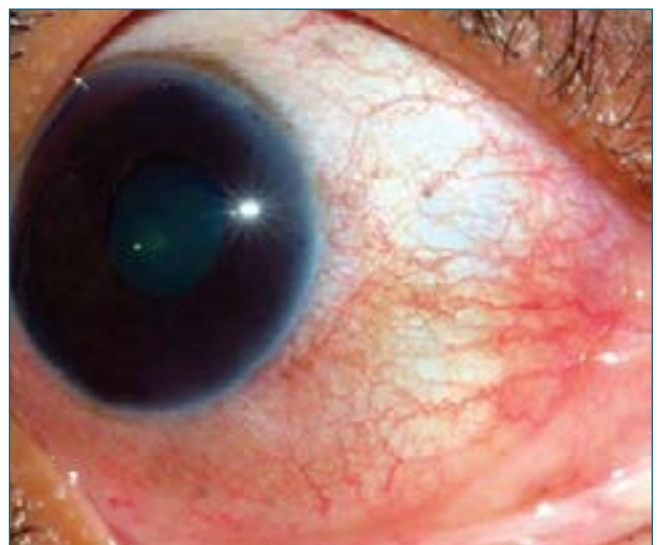
Scleritis

Seek an urgent referral to an ophthalmologist (<24 hours).

Figure 89. Scleritis with scleral thinning and dark choroidal show.

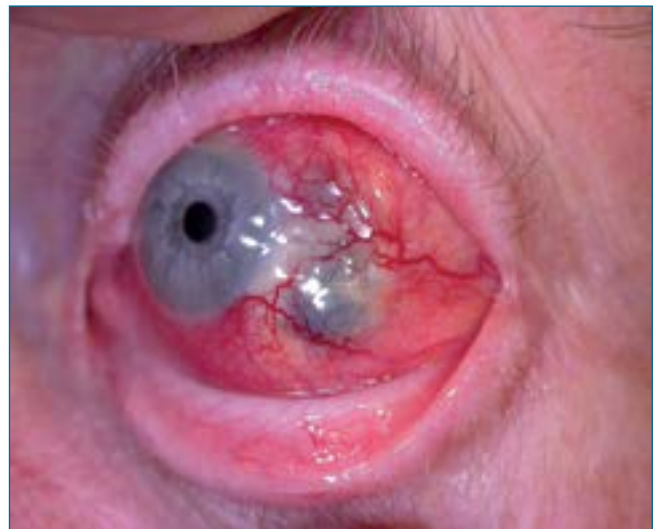

Figure 90. Inferior scleritis.²⁵



History findings

- Painful and red eye
- Pain is a 'deep ache' and often wakes the patient from sleep
- Redness, usually unilateral, and may be localised to the involved area or diffuse
- History of life-threatening vasculitis or connective tissue disease, especially rheumatoid arthritis

Examination findings

- Visual acuity may be reduced
- Globe is tender to palpation through the closed eyelid
- Sclera is thickened and discoloured
- If the sclera is thinned from ongoing inflammation, there may be a dark discolouration which is the pigmented choroid showing through (Figure 89); if there is severe thinning, consider globe perforation

Important differentials

Consider the following:

- Episcleritis occurs when layers superficial to the sclera are inflamed. This may be autoimmune-related or exposure-related, (e.g. wind while cycling or air-conditioning on an aeroplane).
- Conjunctivitis is more diffuse and involves the tarsal conjunctiva.

Initial treatment

- Consult an ophthalmologist
- Consider vasculitis and autoimmune screen
- May consider systemic NSAIDs and steroids on consultation with an ophthalmologist and rheumatologist

Section communication checklist

Consider the following:

- ☒ Onset and duration of symptoms
- ☒ Painful/not painful
- ☒ Distribution of redness (localised or diffuse/involving tarsal conjunctiva)
- ☒ Purely unilateral, or some contralateral symptoms
- ☒ Best (pinhole) visual acuity of each eye
- ☒ Eyelids involvement (red or swollen)
- ☒ Cornea normal or not normal, i.e. cloudy, opacities or fluorescein staining
- ☒ Anterior chamber normal or not normal, i.e. deep, presence of anterior chamber cells, blood or hypopyon
- ☒ Iris normal, i.e. round, equal, reactive pupils with normal iris detail visible
- ☒ Equal red reflexes

Specific communication checklist

Consider the following:

- ☒ Ask about pain waking the patient from sleep
- ☒ Systems review, especially for autoimmune disease

Subconjunctival haemorrhage

Figure 91. Subconjunctival haemorrhage of the temporal bulbar conjunctiva.²⁶

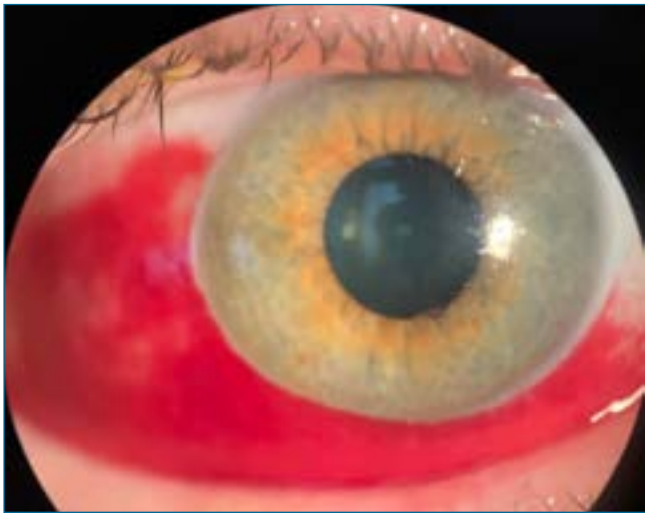


Figure 92. Subconjunctival haemorrhage after one week, extending nasally and temporally.²⁷

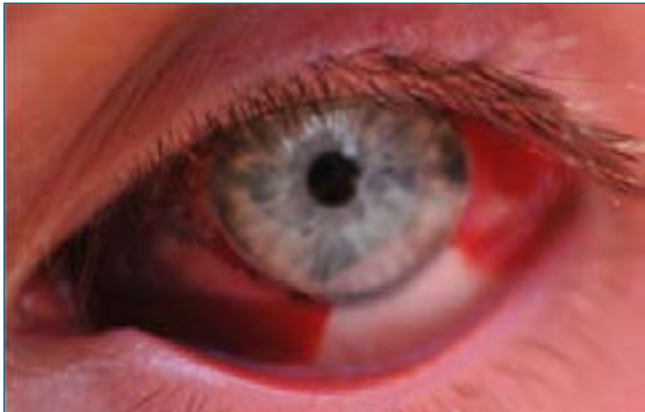
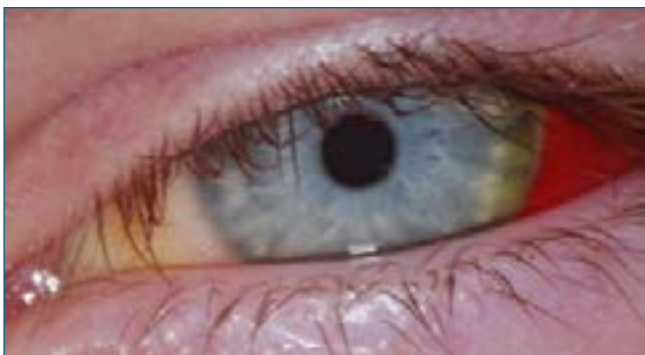
Figure 93. Four weeks after haemorrhage.²⁸



History findings

Consider the following:

- A subconjunctival haemorrhage is discovered on waking when looking in the mirror, as it is otherwise largely asymptomatic.
- It may be associated with mild grittiness or dryness of the eye if the haemorrhage is raised and causes adjacent corneal drying.
- It is possibly associated with minor injuries including eye-rubbing, foreign body and Valsalva.
- It is common with the use of antiplatelet agents and anticoagulants.

Examination findings

- Superficial blood under the conjunctivae
- Unilateral, localised and sharply circumscribed at the limbus
- Underlying sclera is not visible
- No inflammation, pain or discharge
- Vision is unchanged

Important differentials

Consider the following:

- Open-globe injury (penetrating eye injury): a subconjunctival haemorrhage that is large, extends posteriorly or with a suspicious history of penetrating eye injury (involving a sharp object), ruptured globe (from severe blunt trauma) or intraocular foreign body should be examined thoroughly, as the haemorrhage may mask an underlying scleral wound.
- Examine the visual acuity, pupil shape and reactions, extraocular movements, anterior segment on the slit lamp, red reflex and fundoscopy.

Initial treatment

- Check and manage blood pressure
- For patients on Warfarin, check INR and manage accordingly
- Use lubricating drops if gritty or dry eye symptoms present
- Refer to an ophthalmologist if the condition worsens or pain develops

Section communication checklist

Consider the following:

- ☒ Onset and duration of symptoms
- ☒ Painful/not painful
- ☒ Distribution of redness (localised or diffuse/involving tarsal conjunctiva)
- ☒ Purely unilateral, or some contralateral symptoms
- ☒ Best (pinhole) visual acuity of each eye
- ☒ Eyelids involvement (red or swollen)
- ☒ Cornea normal or not normal, i.e. cloudy, opacities or fluorescein staining
- ☒ Anterior chamber normal or not normal, i.e. deep, presence of anterior chamber cells, blood or hypopyon
- ☒ Iris normal, i.e. round, equal, reactive pupils with normal iris detail visible
- ☒ Equal red reflexes

Trichiasis

A condition where eyelashes (not eyelids) are abnormally turned in towards the eye.

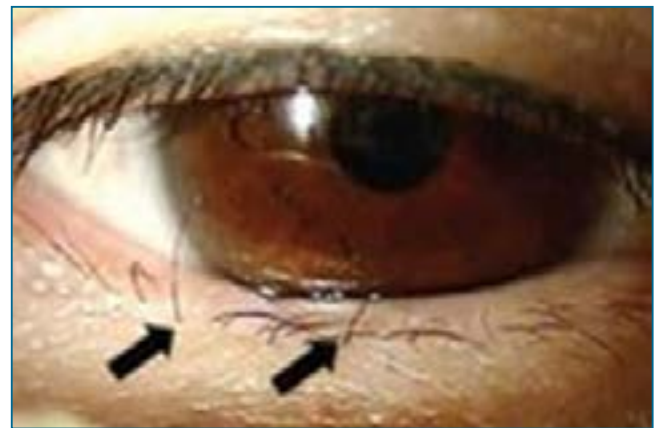
History findings

- Ocular irritation, foreign body sensation and tearing

Examination findings

- Inturned eyelashes which may rub on the cornea with blinking
- Corneal staining close to the lash location (punctate erosions or a frank corneal ulcer)

Figure 94. An image of the preoperative eyelashes.²⁹



Initial treatment

- Epilate offending lashes
- Lubricate every 2–3 hours using preservative-free lubricant

Notes

Consider the following:

- Trichiasis often arises from years of blepharitis, resulting in a distortion of the eyelid margin.
- Epilated lashes will often grow back after 6 weeks. More permanent treatment (laser, freezing or electrolysis of lash follicle) may be performed by an ophthalmologist.

Ophthalmology referral is indicated if concerns for cornea, e.g. recurrent abrasions.

Section communication checklist

Consider the following:

- ☒ Onset and duration of symptoms
- ☒ Painful/not painful
- ☒ Distribution of redness (localised or diffuse/involving tarsal conjunctiva)
- ☒ Purely unilateral, or some contralateral symptoms
- ☒ Best (pinhole) visual acuity of each eye
- ☒ Eyelids involvement (red or swollen)
- ☒ Cornea normal or not normal, i.e. cloudy, opacities or fluorescein staining
- ☒ Anterior chamber normal or not normal, i.e. deep, presence of anterior chamber cells, blood or hypopyon
- ☒ Iris normal, i.e. round, equal, reactive pupils with normal iris detail visible
- ☒ Equal red reflexes

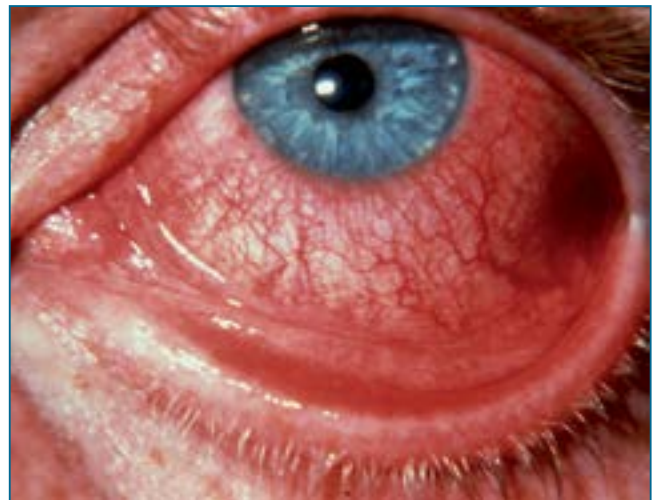Viral conjunctivitis



Highly contagious. Observe Standard Precautions.

- NSW Health [Epidemic Keratoconjunctivitis fact sheet](#)
- RANZCO Infection Control Guidelines [Fact Sheet for Epidemic Keratoconjunctivitis \(EKC\)](#)
- Viral conjunctivitis is most commonly caused by adenovirus; however, HSV and VZV, (e.g. part of V1 shingles) should be considered as causes

Figure 95. Viral conjunctivitis.



History findings

Consider the following:

- Undertake a contact history with person/s affected with red eye(s) or upper respiratory tract infection symptoms (especially children).
- Viral conjunctivitis involves a burning sensation and watery discharge (different from purulent exudate in bacterial infections).
- It classically begins in one eye with spread to the other after 3 days.

Examination findings

- Unilateral or bilateral red eye with involvement of the whole conjunctiva, including tarsal conjunctiva on eyelid eversion (use gloves for infection control)
- Lid eversion may also reveal follicles (small pale raised lumps of 0.5–1mm between the injected vessels)
- Preauricular lymphadenopathy
- Visual acuity is usually mostly normal (6/9 or better)
- Check pupils for anisocoria (consider iritis as a differential diagnosis if miosis is present)

Initial treatment

Consider the following:

- Limit transmission: perform frequent handwashing, use separate tissues, avoid contact with others while infectious (about 10–12 days from onset of symptoms), disinfect surfaces, (e.g. handles and light switches) and avoid sharing of towels and pillows.
- Provide symptomatic relief using cool compresses and preservative-free lubricating drops, gels or ointments every 1–2 hours.
- Administer antibiotic drops if ulcers are present as prophylaxis.
- Avoid steroids.
- Seek a more urgent ophthalmology referral (within 24 hours) if photophobia occurs and there is a marked decrease in visual acuity.

Notes

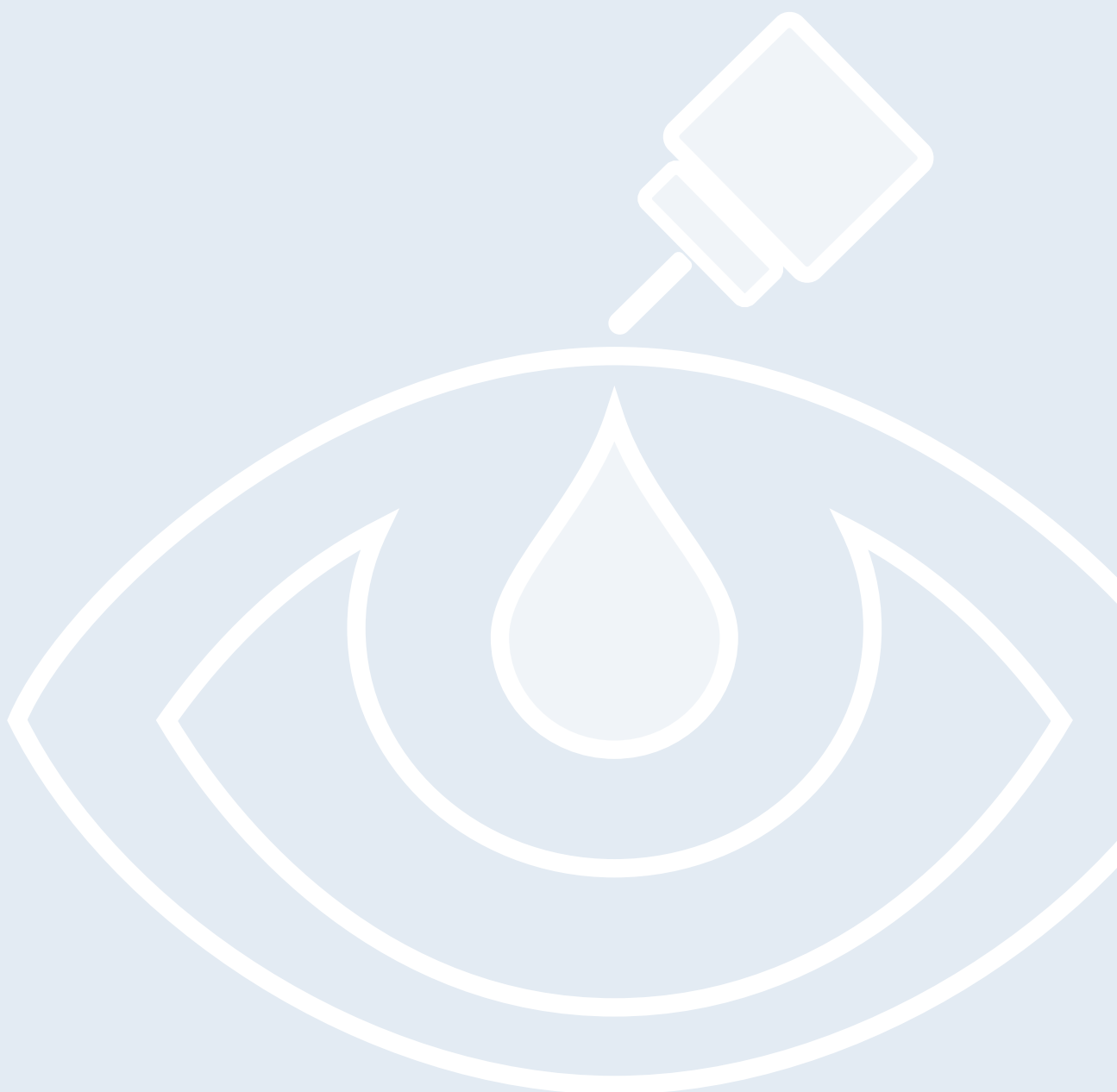- Resolution may take several weeks.
- If it lasts longer than 3 weeks, consider other diagnoses, including chlamydia conjunctivitis and other diagnoses, (e.g. episcleritis, scleritis, iritis and HSV keratitis).
- Consider other diagnoses if presented with a unilateral red eye of >3 days duration.

Section communication checklist

Consider the following:

- ☒ Onset and duration of symptoms
- ☒ Painful/not painful
- ☒ Distribution of redness (localised or diffuse/involving tarsal conjunctiva)
- ☒ Purely unilateral, or some contralateral symptoms
- ☒ Best (pinhole) visual acuity of each eye
- ☒ Eyelid involvement (red or swollen)
- ☒ Cornea normal or not normal, i.e. cloudy, opacities or fluorescein staining
- ☒ Anterior chamber normal or not normal, i.e. deep, presence of anterior chamber cells, blood or hypopyon
- ☒ Iris normal, i.e. round, equal, reactive pupils with normal iris detail visible
- ☒ Equal red reflexes

Treatments



Treatments

Ocular drugs

For detailed information on ocular drugs, refer to the Sydney Eye Hospital's [Ophthalmic Pharmacopoeia App](#).

Eye drops

Eye drops can get washed out if they are instilled in quick succession. Therefore, wait at least 5–10 minutes between eye drop instillation for maximum effect.

Many eye drops are available as commercially prepared Minims that can look indistinguishable from each other. Check carefully as you prepare an eye drop, then double-check immediately before instillation.

In the rare situation that you need to prepare the periocular skin prior to a procedure, you can use dilute Betadine with an equal amount of saline (to give Betadine 5%) or aqueous chlorhexidine (do NOT use the chlorhexidine, which comes mixed with alcohol). A drop of either of these substances can go into the eye, provided there is a topical anaesthetic already in place and the eye is irrigated thoroughly afterwards.

Topical anaesthetic

Topical anaesthetic is used to improve patient comfort and as an aid to examination. Anaesthetic effects last between 10 and 20 minutes, so warn the patient that the relief they feel will be temporary. Ensure that topical anaesthetic is instilled before irrigating for chemical injuries.

It is not standard practice to prescribe topical anaesthetic for patients to take home as its safety has not been established and it may either cause or mask the development of complications.

Common anaesthetics include Amethocaine 0.1% (tetracaine) and benoxinate 0.4%, which are usually available in commercially prepared Minims. It is also possible to use drops of lignocaine 1–2% (preferably without adrenaline), identical to the subcutaneous preparation.

Using topical anaesthetic to treat epithelial defects

The regular use of topical anaesthetic to improve comfort while simple corneal epithelial defects heal is controversial. Studies have shown that topical anaesthetic is toxic to corneal epithelial and stromal cells with prolonged use. Several case series have not demonstrated any adverse effects; however, safety has not been adequately established. At the time of writing the issue remains unresolved.

If you are considering prescribing topical anaesthetic to improve a patient's comfort while an epithelial defect heals, please remember that safety has not been established. While corneal epithelial defects are very painful, they will usually heal within a few days.

Fluorescein

Fluorescein is used to diagnose corneal epithelial defects. It is generally available in Minims at 2% concentration (orange), at 0.2% concentration combined with lignocaine anaesthetic (yellow) or in fluorescein strips moistened with normal saline, then touched against the conjunctiva or in the fornix (NOT the cornea itself).

The optical properties of fluorescein are that it absorbs blue light and reflects green light. The chemical properties of fluorescein are that it binds

to denuded areas of epithelium, and elsewhere is washed away by the tear film. This is the basis for its use: to detect corneal epithelial defects (hence the importance of using blue light and not green). It also binds to mucus strands, which can be differentiated from epithelial defects by their movement on blinking.

Orange-coloured 2% fluorescein does not fluoresce because it is too concentrated. It is used to detect corneal leaks, which is done by instilling it at full concentration on the eye and then examining it under cobalt blue light at the slit lamp. At the point of the corneal wound, aqueous leaking out will dilute the fluorescein and it will fluoresce (appearing as a green rivulet trickling down through the orange fluorescein in the tear film). This is known as a Seidel test, and a leaking wound is termed 'Seidel positive'.

For the same reason, if you administer a large drop of orange 2% fluorescein into the eye looking for an epithelial defect, you will probably not be able to see one for several minutes, and in that time the orange fluorescein will stain the cornea and leak into the anterior chamber, rendering further examination of the anterior chamber more difficult. The key to using it is to administer a very small drop into the eye and use the patient's tear film to disperse and dilute it. Also be aware that fluorescein stains contact lenses, skin and clothing (albeit temporarily), so be careful using it.

Mydriatic drops

Dilating the patient's pupil allows fundus examination and is also used in situations of intraocular inflammation to paralyse and enlarge the pupil. As mentioned elsewhere, it is not appropriate to dilate a patient's eyes in the ED before speaking with an ophthalmologist (or, in some cases, a neurosurgeon). It usually takes 15 to 20 minutes for the drops to work and vision is

affected for several hours, so patients are not permitted to drive following dilation.

Commonly available mydriatic drops are tropicamide 1%, phenylephrine at 2.5% and 10%, cyclopentolate 1% (or 0.5%) and atropine 1% (one drop has an effect for 7–10 days), in both Minims and bottles. Many textbooks will refer to homatropine, which is a drop that is no longer manufactured but can generally be replaced by cyclopentolate.

Topical antibiotics

These are used both as prophylaxis and treatment for microbial infections and commonly available preparations include chloramphenicol, ofloxacin, ciprofloxacin, gentamicin and tobramycin. Some are available as drops, others as ointments and some as both. In certain situations, other antibiotics can be compounded by pharmacies for use as an eye drop.

The most common topical antiviral is acyclovir ointment, which is used for herpetic epithelial keratitis. This condition requires specialist ophthalmology management.

Ocular lubricating drops

Lubricating drops are used to treat dry eye, which is very common. Lubricating drops are generally available in two forms – preserved (in bottles) and non-preserved (in Minims, or similar ampoules) – and can be purchased over the counter from the chemist. If a patient requires lubricating drops more than four to six times a day, they should use non-preserved drops to lower the risk of toxicity from preservatives. Lubricating gels and ointments are an alternative. They are effective, longer lasting and most applicable for nocturnal use but can blur vision if used during the day.

Topical steroids

Topical steroids are used to treat ocular surface and intraocular inflammation and should only be prescribed by an ophthalmologist due to the substantial risk of complications, including glaucoma, microbial keratitis and cataracts.

Ocular antihypertensives (glaucoma drops)

Ocular antihypertensives are used to lower intraocular pressure in the treatment of glaucoma. Many patients are on these medications because glaucoma is such a common disease. There are a multitude of different drops and drop combinations across four major drug classes. If required for the treatment of acutely elevated pressure, refer to specific advice provided by an ophthalmologist.

Eye pad and shield

It is not wise to pad an eye with minor corneal or conjunctival trauma. A pad placed inappropriately may exacerbate injury while the cornea is anaesthetised, or if the patient is already in pain due to an existing corneal injury. While a pad may be placed in specific situations, always discuss it with an ophthalmologist before doing so. A patient cannot drive with a pad on one eye as it reduces depth perception.

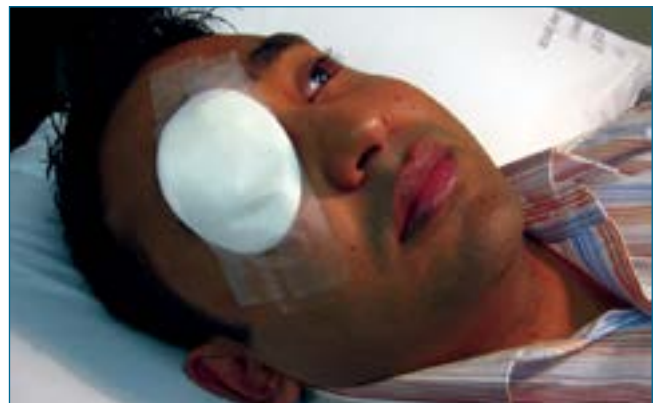It can be tempting to prescribe a topical anaesthetic to patients with corneal epithelial defects to improve comfort during healing. Please be aware that the safety of doing this has not been established and it remains controversial.

Technique for eye pad



[Video - Eye Padding](#)

Figure 96. Single eye pad.



1. Use one or two pads (stacked on top of each other).
2. Prepare three pieces of tape in advance and have them on hand.
3. Ask the patient to close their eyes, then place the pad on firmly so that the eye remains closed. Tape firmly in place.
4. When applied correctly, the patient's padded eye should remain closed when they open the other eye.
5. The tape should angle away from the mouth. To ensure that the tape is compact on the eye, place the pieces parallel to each other.
6. It may help to put chloramphenicol ointment in the eye prior to applying the pad or use a small piece of Jelonet between the pad and the closed eyelid.

Notes

If the eye opens underneath the eye pad, it may not be noticed by the patient and they can sustain significant corneal injury by the time the pad is removed.

Technique for an eye shield

1. Use either a clear plastic shield or a truncated disposable cup.
2. Place it over the eye without putting any pressure on the orbit. Make sure the rim of the shield or the cup is resting on the bony orbital margin.



In situations of globe rupture do NOT put anything underneath the shield in contact with the eye as the goal is to avoid any pressure on the globe whatsoever.

Figure 97. Shield made from a disposable cup.



Figure 98. Disposable cup.

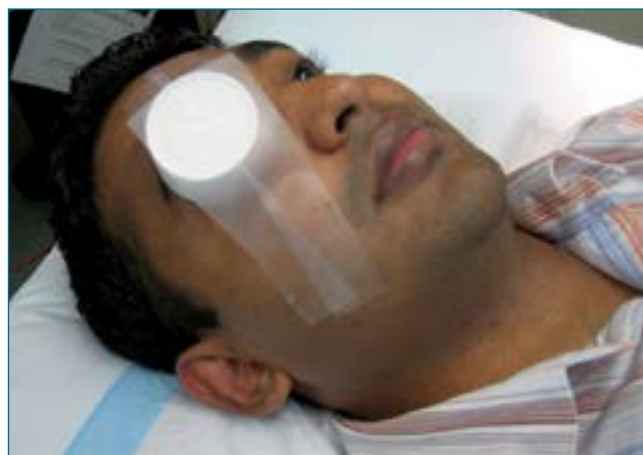
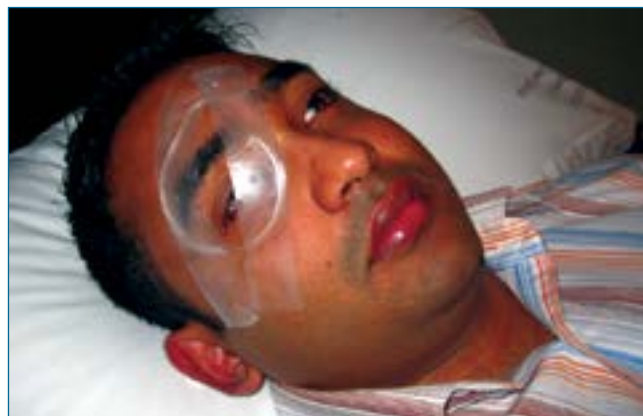
Figure 99. Eye shield.

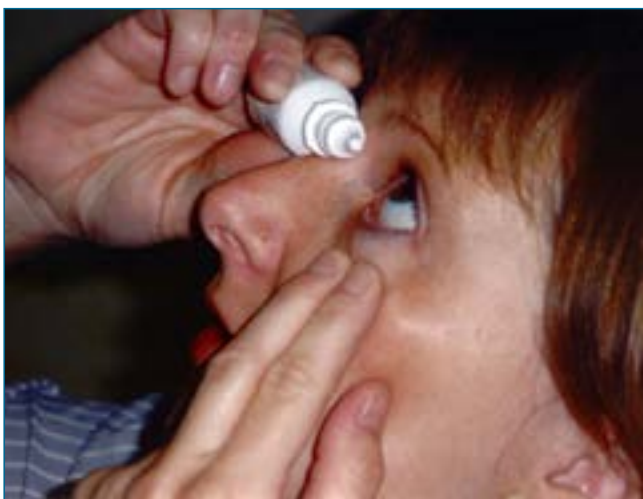

How to put in eye drops

Self-instillation

1. Wash hands.
2. Uncap the bottle/tube.
3. Tilt your head up.
4. Use the hand on the opposite side to hold the bottle resting on the bridge of the nose, taking care not to touch any surfaces with the bottle tip.
5. Pull down the lower lid with the fingers of the same side so that a visible pocket forms in the space behind the lid.
6. Gently squeeze the bottle to deliver 1 or 2 drops.
7. Shut the eyelid for approximately 1 minute.
8. Wipe away excess drops/ointment from your face.
9. Re-cap the bottle.
10. Wash hands.

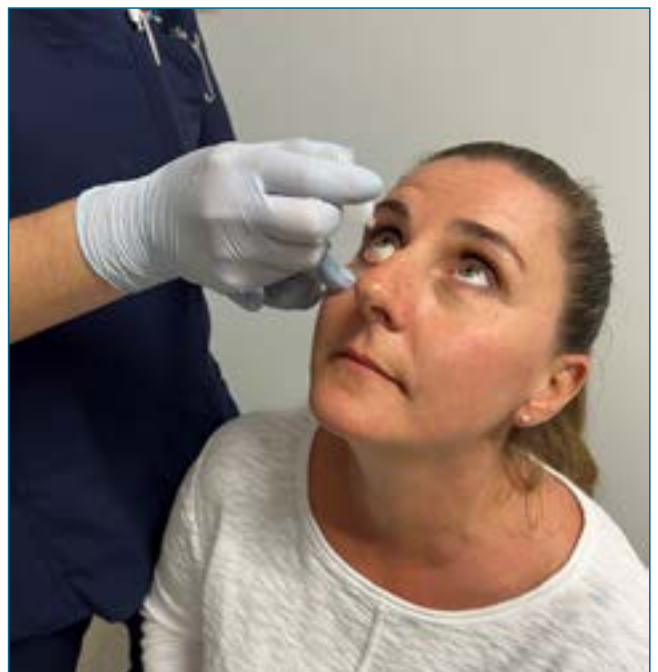Figure 100. Self-instillation of eye drops.



Assisted instillation

1. Wash hands.
2. Uncap the container or twist off the tab.
3. Pull the lower eyelid gently down with forefinger to form a pocket.
4. Tilt the head slightly back and look up.
5. Hold the bottle gently between the thumb and forefinger and gently squeeze the recommended number of drops into the pocket formed.
6. Do not touch the eye with bottle tip.
7. Shut the eye and move the eyeball from side to side to spread the medication.
8. Wash hands.

Figure 101. Drops administered by a healthcare worker or family member.



References

1. Prabhasawat P, Ekpo P, Uprasertkul M, et al. Efficacy of cultivated corneal epithelial stem cells for ocular surface reconstruction. Clin Ophthalmol. 2012;6:1483-92. DOI: 10.2147/OPTH.S33951.
2. Choi YJ, Jung MS, Kim SY. Retinal hemorrhage associated with perinatal distress in newborns. Korean J Ophthalmol. 2011 Oct;25(5):311-6. DOI: 10.3341/kjo.2011.25.5.311.
3. Zehetner C, Bechrakis NE. White centered retinal hemorrhages in vitamin b(12) deficiency anemia. Case Rep Ophthalmol. 2011 May;2(2):140-4. DOI: 10.1159/000328123.
4. Vijaya L, Manish P, Ronnie G, et al. Management of complications in glaucoma surgery. Indian J Ophthalmol. 2011 Jan;59 Suppl(Suppl1):S131-40. DOI: 10.4103/0301-4738.73689.
5. Thompson D, Stanescu C, Pryor P, et al. Retrobulbar hematoma from warfarin toxicity and the limitations of bedside ocular sonography. West J Emerg Med. 2010 May;11(2):208-10.
6. Wang Y, Wang XH, Tian MM, Xie CJ, Liu Y, Pan QQ, Lu YN, CC BY 4.0, via Wikimedia Commons (accessed October 2023). Available from: https://commons.wikimedia.org/wiki/File:Oculomotor_nerve_palsy.png
7. Mohammad T Masoud, Ajmal Rehman and Yusuf Shaikh, CC BY 2.0, via Wikimedia Commons (accessed October 2023). Available from: https://commons.wikimedia.org/wiki/File:Abducens_palsy.jpg
8. Russell Neches (Rneches), CC BY-SA 3.0, via Wikimedia Commons (accessed October 2023). Available from: https://commons.wikimedia.org/wiki/File:Central_serous_retinopathy.jpg
9. Jonathan Trobe, M.D., CC BY 3.0, via Wikimedia Commons (accessed October 2023). Available from: https://commons.wikimedia.org/wiki/File:Acute_Angle_Closure-glaucoma.jpg
10. Cumulus at Dutch Wikipedia, CC BY-SA 3.0, via Wikimedia Commons (accessed October 2023). Available from: <https://commons.wikimedia.org/wiki/File:Myasthenia.jpg>
11. CDC/Dr. Sellers/Emory University, Public domain, via Wikimedia Commons (accessed October 2023). Available from: https://commons.wikimedia.org/wiki/File:Bilateral_exophthalmos.jpg
12. National Eye Institute/National Institutes of Health, Public domain, via Wikimedia Commons (accessed October 2023). Available from: https://commons.wikimedia.org/wiki/File:Slit_lamp_photograph_showing_retinal_detachment_in_Von_Hippel-Lindau_disease_EDA08.JPG
13. La Rosa M, Lionetti E, Reibaldi M, et al. Allergic conjunctivitis: a comprehensive review of the literature. Ital J Pediatr. 2013 Mar 14;39:18. doi: 10.1186/1824-7288-39-18.
14. Jonathan Trobe, M.D., CC BY 3.0, via Wikimedia Commons (accessed October 2023). Available from: <https://creativecommons.org/licenses/by/3.0>
15. London NJ, Garg SJ, Moorthy RS, et al. Drug-induced uveitis. J Ophthalmic Inflamm Infect. 2013 Mar 25;3(1):43. DOI: 10.1186/1869-5760-3-43.
16. Grook Da Oger, CC BY-SA 3.0, via Wikimedia Commons (accessed October 2023). Available from: <https://creativecommons.org/licenses/by-sa/3.0>

17. E van Herk, CC BY-SA 3.0, E van Herk, CC BY-SA 3.0, via Wikimedia Commons (accessed October 2023). Available from: <https://creativecommons.org/licenses/by-sa/3.0>
18. Asagan, CC BY-SA 3.0, via Wikimedia Commons (accessed October 2023). Available from: <https://creativecommons.org/licenses/by-sa/3.0>
19. Seo KS, Lee HM, Shin HJ, et al. Coinfection with herpes zoster ophthalmicus and oriental eye worm in a rural woman: the first report of an unusual case. *Ann Dermatol*. 2014 Feb;26(1):125-6. DOI: 10.5021/ad.2014.26.1.125.
20. Babu K, Maralihalli RE. Insect wing tarsal foreign body causing conjunctival granuloma and marginal keratitis. *Indian J Ophthalmol*. 2009 Nov-Dec;57(6):473-4. DOI: 10.4103/0301-4738.57154.
21. Columbia University Irving Medical Center. Neovascular glaucoma. New York, USA: Columbia University; 2023 (accessed October 2023). Available from: <https://www.vagelos.columbia.edu/departments-centers/ophthalmology/education/digital-reference-ophthalmology/glaucoma/angle-closure-glaucoma/neovascular-glaucoma>
22. CDC/ J. Pledger, Public domain, via Wikimedia Commons (accessed October 2023). Available from: https://commons.wikimedia.org/wiki/File:Gonococcal_ophthalmia_neonatorum.jpg
23. Afrodriguezg, CC BY-SA 3.0, via Wikimedia Commons (accessed October 2023). Available from: [https://commons.wikimedia.org/wiki/File:Celulitis_Periorbitaria_\(Preseptal\).JPG](https://commons.wikimedia.org/wiki/File:Celulitis_Periorbitaria_(Preseptal).JPG)
24. Park CY, Choi JS, Lee SJ, et al. Cyclooxygenase-2-expressing macrophages in human pterygium co-express vascular endothelial growth factor. *Mol Vis*. 2011;17:3468-80.
25. Kamath YS, Rathinam SR, Kawali A. Ocular toxoplasmosis associated with scleritis. *Indian J Ophthalmol*. 2013 Jun;61(6):295-7. DOI: 10.4103/0301-4738.111130.
26. Daniel Flather, CC BY-SA 3.0, via Wikimedia Commons (accessed October 2023). Available from: https://commons.wikimedia.org/wiki/File:Subconjunctival_hemorrhage_eye.JPG
27. Therealbs 2002, CC BY-SA 3.0, via Wikimedia Commons (accessed October 2023). Available from: [https://commons.wikimedia.org/wiki/File:Subconjunctival_hemorrhage_before_after_\(cropped\).jpg](https://commons.wikimedia.org/wiki/File:Subconjunctival_hemorrhage_before_after_(cropped).jpg)
28. Therealbs 2002, CC BY-SA 3.0, via Wikimedia Commons (accessed October 2023). Available from: [https://commons.wikimedia.org/wiki/File:Subconjunctival_hemorrhage_before_after_\(cropped4weeks\).jpg](https://commons.wikimedia.org/wiki/File:Subconjunctival_hemorrhage_before_after_(cropped4weeks).jpg)
29. Kim GN, Yoo WS, Kim SJ, et al. The effect of 0.02% mitomycin C injection into the hair follicle with radiofrequency ablation in trichiasis patients. *Korean J Ophthalmol*. 2014 Feb;28(1):12-8. DOI: 10.3341/kjo.2014.28.1.12.

Appendix: Evidence base

PubMed search terms

((("Eye Diseases"[Mesh] OR "Eye Injuries"[Mesh] OR "eye disease*" [Title] OR "eye injur*" [Title]) AND ("Emergency Treatment"[Mesh] OR ("emergenc*" [Title] AND "treat*" [Title])) OR ("ocular emergenc*" [Title] OR "eye emergenc*" [Title])) AND ("Guideline" [Publication Type] OR "Practice Guideline" [Publication Type] OR "guideline*" [Title] OR "principle*" [Title] OR "procedure*" [Title] OR "diagnos*" [Title] OR "management" [Title])) NOT ("COVID" [Title/Abstract]) AND (english[Filter]) AND (2009:2023[pdat]))

Google search terms

eye injury OR eye disease OR eye emergency AND guidelines OR management

Inclusion and exclusion criteria

Inclusion	Exclusion
<ul style="list-style-type: none"> Published in English Studies reporting empirical data, including modelling studies, and systematic review articles Published between 2009 and present 	<ul style="list-style-type: none"> Letters, comments, editorials, study protocols, case reports or conference abstracts Abstract only Studies or results related to COVID-19

Bibliography

- Al-Dhibi HA, Al-Mahmood AM, Arevalo JF. A systematic approach to emergencies in uveitis. Middle East Afr J Ophthalmol. 2014 Jul-Sep;21(3):251-8. DOI: 10.4103/0974-9233.134687
- Biousse V, Nahab F, Newman NJ. Management of Acute Retinal Ischemia: Follow the Guidelines! Ophthalmology. 2018 Oct;125(10):1597-607. DOI: 10.1016/j.ophtha.2018.03.054
- Chou HD, Chen KJ, Kang EY, et al. Eye irrigation as a first-line treatment and diagnostic method for emergency department patients who complain of ocular foreign bodies. Sci Rep. 2021 Dec 3;11(1):23386. DOI: 10.1038/s41598-021-02989-3
- Cugati S, Varma DD, Chen CS, et al. Treatment options for central retinal artery occlusion. Curr Treat Options Neurol. 2013 Feb;15(1):63-77. DOI: 10.1007/s11940-012-0202-9
- Dasgupta B. Concise guidance: diagnosis and management of giant cell arteritis. Clin Med (Lond). 2010 Aug;10(4):381-6. DOI: 10.7861/clinmedicine.10-4-381
- Department of Health and Aged Care. Summary of ophthalmic emergency predictors (OEP) for the ATS [Internet]. Australia: Department of Health and Aged Care; 2013 Jan 21 [cited 2023 July 13]. Available from: <https://www1.health.gov.au/internet/publications/publishing.nsf/Content/triageqrg~triageqrg-eye>.
- Dua HS, Ting DSJ, Al Saadi A, et al. Chemical eye injury: pathophysiology, assessment and management. Eye (Lond). 2020 Nov;34(11):2001-19. DOI: 10.1038/s41433-020-1026-6
- Eslani M, Baradaran-Rafii A, Movahedan A, et al. The ocular surface chemical burns. J Ophthalmol. 2014;2014:196827. DOI: 10.1155/2014/196827

- Hayreh SS. Management of ischemic optic neuropathies. *Indian J Ophthalmol*. 2011 Mar-Apr;59(2):123-36. DOI: 10.4103/0301-4738.77024
- Heath Jeffery R, Dobes J, Chen F. Eye injuries: Understanding ocular trauma. *Australian Journal for General Practitioners*. 2022 07/01;51:476-82.
- Hodge C, Lawless M. Ocular emergencies. *Aust Fam Physician*. 2008 Jul;37(7):506-9.
- Lindfield D, Das-Bhaumik R. Emergency department management of penetrating eye injuries. *Int Emerg Nurs*. 2009 Jul;17(3):155-60. DOI: 10.1016/j.ienj.2009.01.003
- Mac Grory B, Schrag M, Biousse V, et al. Management of Central Retinal Artery Occlusion: A Scientific Statement From the American Heart Association. *Stroke*. 2021 Jun;52(6):e282-e94. DOI: 10.1161/str.0000000000000366
- Mbonde AA, O'Carroll CB, Dulamea OA, et al. Current Guidelines on Management of Amaurosis Fugax and Transient Ischemic Attacks. *Asia Pac J Ophthalmol (Phila)*. 2022 Mar-Apr 01;11(2):168-76. DOI: 10.1097/apo.0000000000000511
- Michels TC, Ivan O. Glaucoma: Diagnosis and Management. *Am Fam Physician*. 2023 Mar;107(3):253-62.
- Miller SC, Flitsos MJ, Justin GA, et al. Global Current Practice Patterns for the Management of Open Globe Injuries. *Am J Ophthalmol*. 2022 Feb;234:259-73. DOI: 10.1016/j.ajo.2021.08.003
- Nuzzi R, Buschini E, Actis AG. Ophthalmic evaluation and management of traumatic accidents associated with retinal breaks and detachment: a retrospective study. *Eur J Ophthalmol*. 2012 Jul-Aug;22(4):641-6. DOI: 10.5301/ejo.5000088
- O'Connor PM, Crock CT, Dhillon RS, et al. Resources for the management of ocular emergencies in Australia. *Emerg Med Australas*. 2011 Jun;23(3):331-6. DOI: 10.1111/j.1742-6723.2011.01411.x
- Optometry Australia. Clinical practice guide for the diagnosis, treatment and management of anterior eye conditions [Internet]. Melbourne, Australia: Optometry Australia; 2018 Apr [cited 2023 Jul 13]. Available from: https://www.optometry.org.au/wp-content/uploads/Professional_support/Guidelines/anterior_eye_clinical_practice_guide_2_.pdf.
- Serrano F, Stack LB, Thurman RJ, et al. Traumatic eye injuries: management principles for the prehospital setting. *Jems*. 2013 Dec;38(12):56-62.
- Sethuraman U, Kamat D. The red eye: evaluation and management. *Clin Pediatr (Phila)*. 2009 Jul;48(6):588-600. DOI: 10.1177/0009922809333094
- The Royal Children's Hospital Melbourne. Clinical practice guidelines [Internet]. Melbourne, Australia: The Royal Children's Hospital Melbourne; 2022 Oct [cited 2023 July 13]. Available from: <https://www.rch.org.au/clinicalguide/>.
- The Royal Victorian Eye and Ear Hospital. Emergency department clinical practice guidelines [Internet]. Melbourne, Australia: The Royal Victorian Eye and Ear Hospital; 2023 [cited 2023 July 13]. Available from: <https://eyeandear.org.au/health-professionals/clinical-practice-guidelines/>.
- UpToDate. Approach to diagnosis and initial treatment of eye injuries in the emergency department [Internet]. Massachusetts, USA: UpToDate; 2023 Feb 8 [cited 2023 Jul 18]. Available from: <https://www.uptodate.com/contents/approach-to-diagnosis-and-initial-treatment-of-eye-injuries-in-the-emergency-department>.
- Varma DD, Cugati S, Lee AW, et al. A review of central retinal artery occlusion: clinical presentation and management. *Eye (Lond)*. 2013 Jun;27(6):688-97. DOI: 10.1038/eye.2013.25
- Youn TS, Lavin P, Patrylo M, et al. Current treatment of central retinal artery occlusion: a national survey. *J Neurol*. 2018 Feb;265(2):330-5. DOI: 10.1007/s00415-017-8702-x

Glossary

Term	Definition
Acute angle closure	Acute angle closure glaucoma is caused by a rapid or sudden increase in intraocular pressure (IOP), the pressure inside the eye. Urgent ophthalmologist attention is required.
Age-related macular degeneration (ARMD)	A medical condition that may result in blurred or no vision in the central field of vision. ARMD may be asymptomatic initially.
Amblyopia	Reduced visual acuity that results from deprivation of optimal visual experience during early childhood. Patients are usually aware of a history of amblyopia or 'lazy eye'.
Amsler grid	A tool to detect vision problems resulting from damage to the macular or optic nerves. The tool can be downloaded via the macular haemorrhage wARMD page.
Anisocoria	Asymmetry in pupil size. The degree of asymmetry can differ in light and dark conditions, so measure pupil size in both. Anisocoria is a feature of third cranial nerve palsy (greater difference in dark), Horner syndrome (greater difference in light) and iris trauma.
Anterior chamber (AC)	Anatomy term: the space between the iris and corneal endothelium.
Anterior ischaemic optic neuropathy (AION)	Optic nerve dysfunction secondary to arterial ischaemia of the prelaminar optic disc arteriole. Giant cell arteritis (GCA) is the most common cause.
Arteritic anterior ischaemic optic neuropathy (AAION)	Optic nerve dysfunction secondary to ischaemia of the prelaminar optic disc arterioles with resulting disc swelling and pallor. Giant cell arteritis (GCA) is the most common cause.
Australasian Triage Scale (ATS)	A set of triage categories agreed upon by the Australasian College for Emergency Medicine (ACEM) for use in Emergency Departments. Category 1: Immediate simultaneous assessment and treatment; Category 2: <10 minutes; Category 3: <30 minutes; Category 4: <60 minutes; Category 5: <120 minutes.
Avulsion	Pathologic condition: tearing or wrenching away of a part, e.g. the optic nerve from the globe.
Bacterial keratitis	A vision-threatening bacterial infection of the cornea that can cause loss of vision in severe cases. The rate of progression of symptoms is related to the virulence of the infecting organism. Diagnosis is based on clinical history and slit lamp examination showing the presence of a corneal infiltrate.
Bacterial/ acanthamoebal ulcer	An infective condition of the cornea involving disruption of the epithelial layer with involvement of the corneal stroma. Caused by <i>Acanthamoeba</i> infection.

Term	Definition
Blepharitis	Blepharitis is a common eyelid inflammation that is sometimes associated with a bacterial eye infection.
Bradycardia	A slow heart rate: defined as a heart rate of <60 beats per minute (BPM) in adults.
Canthus	The outer or inner corner of the eye where the upper and lower lids meet.
Carotid-cavernous sinus fistula (CCF)	An abnormal communication between the internal or external carotid arteries and the cavernous sinus.
Cataract	The clouding of a normal lens. The main symptom is blurry vision. Patients may describe vision as looking through a cloudy window. Refer to an ophthalmologist if not already under care.
Central nervous system (CNS)	The retina is brain tissue and is considered part of the central nervous system (CNS). It is the only part of the CNS that can be visualised non-invasively. Seek neurology referral.
Central retinal vein occlusion (CRVO)	A blockage of the main vein in the retina.
Central serous chorioretinopathy/retinopathy	A disease in which a serous detachment of the neurosensory retina occurs over an area of leakage from the choriocapillaris through the retinal pigment epithelium.
Cerebrovascular accident (CVA)	Stroke: reduced blood flow to the brain.
Chalazion	A benign, painless bump or nodule inside the upper or lower eyelid.
Chemosis	Pathologic condition: oedema of the conjunctiva.
Chiasmal pathology	Pathology at the part of the brain where the optic nerves partially cross.
Choroidal rupture	A break in the choroid.
Cicatrix	Scarring that causes shortening of tissue.
Closed globe injury	An eye wall wound that is not full thickness.
Coloboma	A congenital eye development defect. It can be either unilateral or bilateral and can affect a number of different parts of the eye. The detection of a coloboma does not mean that there is a hole in the eye, but that certain structures within the eye are not fully formed.
Conjunctivitis	Inflammation of the conjunctiva. May be infective or not.

Term	Definition
Consensual pupil response	Pupil constriction when light is shone in the other eye.
Contusion	Injury: a bruise or injury without a break in skin/cover.
Cortical blindness	Lesions affecting the occipital lobe or other parts of the posterior visual pathway.
Counting fingers vision (CF)	A level of vision where the patient is just able to repeatedly count how many fingers are held up 30–300cm in front of them with one eye covered and in good light. The patient is unable to see any letters on the Snellen chart.
Decompensated phoria	When the eye moves outward towards the ear or towards the nose or an eye moves upward as compared to the other eye. It has a gradual onset.
Diplopia (double vision)	Symptom/functional defect: double vision.
Direct pupil response	Pupil constriction when light is shone in the eye.
Dry eye	Inflammation of the conjunctiva and cornea of the eye due to inadequate tear secretion.
Ecchymosis	Pathologic condition: bruising.
Ectropion	Eyelid is turned outwards away from the eyeball.
Endophthalmitis	An intraocular infection and severe inflammation of the anterior and/or posterior chambers of the eye which can occur following surgery, intraocular injection and trauma.
Entropion	When the eyelid is turned towards the eyeball.
Epidemic keratoconjunctivitis (EKC)	Viral conjunctivitis. Please see advice from NSW Health Infectious Diseases web page.
Episcleritis	A benign, inflammatory disease affecting the episclera.
Erosions	Pathologic condition: destruction/eating away/loss of corneal epithelium.
Exposure keratopathy	Dryness of the cornea caused by incomplete eyelid closure. Consider causes such as seventh (7th) cranial nerve palsy and Bell's palsy, eyelid ectropion or eyelid scars. Other contributing factors include: Sjögren's syndrome (aqueous tear underproduction), blepharitis (evaporative dry eye), or neurotropic cornea and ulceration, (e.g. HSV or CNS palsy).
Eyelid hygiene	This is an important part of treatment and prevention of blepharitis. Daily routines involve warmth, massage and cleaning the area.

Term	Definition
Eyelid margin	The portion located at the edge of the eyelid.
Flashes	Flashes are a form of photopsia, a visual phenomenon referring to the perception of light in the absence of external light stimuli. Photopsias generated in the eye result from mechanical stimulation of the retina by vitreoretinal traction. These can be triggered by eye movement and are usually in the temporal visual field.
Fluorescein	An orange dye that is used in conjunction with a blue light to detect foreign bodies in the eye.
Floater	The perception of dark spots caused by opacities in the vitreous that are secondary to degenerative vitreous changes. Patients may describe floaters as 'cobwebs' and 'flies' that are more evident with uniform light backgrounds, (e.g. blue sky).
Fornix/fornices	Potential space between the ocular surface and the conjunctival space of the eyelid.
Fourth (4th) cranial nerve palsy	Causes the inability to depress the eye and classically presents as a vertical or torsional binocular diplopia. Because the fourth cranial nerve innervates the superior oblique, which has a less well-defined pattern of action than the rectus muscles, it can be hard to discern an eye movement disorder. As it has the longest intracranial course of all the cranial nerves, the fourth nerve is particularly vulnerable to trauma, but palsy can also be caused by giant cell arteritis (GCA) or compression by a tumour.
Functional visual loss	A decrease in visual acuity that cannot be accounted for by anatomical or physiological findings. Objective assessments should demonstrate a visual acuity better than subjective visual acuity.
Giant cell arteritis (GCA)	A systemic vasculitis affecting medium and large vessels and also known as temporal arteritis. GCA is an eye emergency that commonly presents as anterior ischaemic optic neuropathy (AION). Symptoms include polymyalgia rheumatica, new onset headache (often temporal), scalp tenderness, jaw claudication, tongue claudication, fever and night sweats, loss of weight, generalised muscle pain and weakness and diplopia or transient visual loss.
Glaucoma	A group of eye diseases in which the neurons of the optic nerve at the back of the eye are slowly destroyed.
Globe	The eyeball.

Term	Definition
Hand movements vision (HM)	A level of vision that the patient is just able to repeatedly determine when a hand is held up 30–100cm in front is moving side to side with one eye covered and in good light. The patient is unable to count fingers.
Herpes simplex	A viral disease caused by the herpes simplex virus.
Herpes zoster	This virus commonly affects the ophthalmic branch of the trigeminal nerve (V1). It is also known as shingles. It may or may not involve the eye, which also has sensory innervation from V1. Ophthalmic manifestations include conjunctivitis, scleritis, episcleritis, keratitis iridocyclitis, Argyll Robertson pupil, glaucoma, retinitis, choroiditis, optic neuritis, optic atrophy, retrobulbar neuritis, exophthalmos, lid retraction, ptosis and extraocular muscle palsies.
Heterochromia	A difference in iris colour. It can occur due to congenital Horner syndrome, chronic intraocular inflammation or prolonged use of some glaucoma drops.
Horner syndrome	Caused by a disruption of the sympathetic nervous system. It can cause minor upper lid ptosis, anisocoria (affected pupil smaller), less sweating on the affected side of the face (anhidrosis) and a lighter-coloured pupil on that side (heterochromia) if long-standing or congenital.
Hyperaemia	Clinical sign: increased blood flow. Congestion of conjunctival blood vessels.
Hypopyon	A visible collection of inflammatory cells in the anterior chamber of the eye.
Ice test	Myasthenia gravis (MG) diagnostic test: an ice pack is applied to a droopy eyelid for 2–5 minutes and then the eyelid is examined for improvement of ptosis.
Identify, Situation, Background, Assessment and Recommendation (ISBAR)	A tool to improve patient safety by standardising communication and the transfer of critical information.
Idiopathic intracranial hypertension (IIH)	A neurological disorder that is characterised by increased intracranial pressure in the absence of a tumour or other disease. Commonly also called pseudotumour cerebri.
Idiopathic orbital inflammatory disease	An inflammation of soft tissue involving any area of the orbit.
Infiltrate	A corneal infiltrate is an aggregate of white blood cells located within the corneal stroma. It usually suggests active bacterial keratitis. There is often an overlying corneal ulcer, which stains with fluorescein.

Term	Definition
Intermediate/posterior uveitis	Uveitis is the inflammation of the uvea. Intermediate uveitis (also known as pars planitis or cyclitis) is the inflammation of tissues in the area just behind the iris and lens of the eye. Posterior uveitis (also known as choroiditis) refers to inflammation of the choroid (back part of the uvea). Posterior uveitis may affect the retina and/or the optic nerve and may lead to permanent loss of vision. It is rare.
Intermittent angle closure	Intermittent episodes of angle closure glaucoma that resolve between attacks. Symptoms include headache, eye pain or occasional halos around lights. Over time, these episodes result in peripheral anterior synechiae (PAS), which can cause permanent elevation of intraocular pressure (IOP) (chronic angle closure glaucoma).
Intraocular pressure (IOP)	Fluid pressure inside the eye.
Iridoschisis	Pathologic condition: splitting of the iris/structural formation of a hole in the iris.
Iritis	Inflammation that affects the iris. The iris is a part of the middle layer of the eye (uvea), so iritis is a type of uveitis, more accurately termed anterior uveitis.
Ischaemia	Pathological condition: localised ischaemia caused by arterial constriction.
Keratitis	Infection or inflammation of the cornea.
Lacrimal drainage apparatus	The system containing the orbital structures for tear production and drainage.
Lagophthalmos	Inability to close the eye. Classically caused by seventh nerve palsy but can also occur due to traumatic disruption of the eyelids. If severe, it can lead rapidly (within hours) to corneal exposure, irreversible scarring and blindness.
Lens dislocation	A lens that has moved out of position because some or all of the supporting ligaments have broken.
Leukocoria	A white, rather than red, reflex when the retina is illuminated from a distance. A red reflex is normally assessed with a direct ophthalmoscope shining a light into both eyes from a distance – a reflected red glow is normally observed – but can also be observed from camera flashes. The life-threatening cause that must urgently be excluded is retinoblastoma, a cancer of the retina that usually occurs in children.

Term	Definition
Light perception (PL or LP)	A level of vision where, with one eye completely covered, the patient is repeatedly able to determine when a very bright light is shone on their eye from about 10cm away. Ensure there are no auditory cues, (e.g. clicking of light switches). The patient is unable to see hand movements.
Limbus	The corneal limbus is the border between the cornea and the sclera.
Macular pathology, (e.g. macular haemorrhage)	The macula is the central region of the retina and is situated at the posterior pole of the eye. It is the part of the retina that produces central vision. Pathology or disease in this area are varied and include oedema and macular haemorrhage, both of which can be caused by age-related macular degeneration and central serous chorioretinopathy. Seek ophthalmologist referral.
Migraine	A primary headache disorder characterised by recurrent headaches that are moderate to severe and typically unilateral. Migraine is the most common reason for aura.
Miosis	The excessive constriction of the pupil of the eye relative to the amount of light the pupil receives. Causes can include drugs, (e.g. opioids, nicotine products, antipsychotics, imidazolines and antiemetics) or disease.
Myasthenia gravis (MG)	Ocular myasthenia gravis is a form of myasthenia gravis in which the muscles that move the eyes and control the eyelids are weakened, causing double vision and/or drooping eyelids. Symptoms tend to be worse at the end of the day.
Mydriasis	The dilation of the pupil of the eye.
Myopic	Short-sighted.
Neoplasm (orbital, intracranial)	An abnormal growth of tissue that can be benign or malignant. Also called tumour.
Neovascular glaucoma (NVG)	Classified as a secondary glaucoma. Delayed diagnosis or poor management can result in complete loss of vision or even the loss of the globe itself. Patients may present with severe pain. Seek urgent referral to an ophthalmologist.
No perception of light (NPL)	A level of vision where, with one eye covered, the patient is unable to reliably perceive light. Compare light perception.
Non-accidental injury (NAI)	A non-accidental injury (NAI) is defined as any abuse purposefully inflicted on a person.

Term	Definition
Non-arteritic anterior ischaemic optic neuropathy (NAION)	Optic nerve dysfunction secondary to ischaemia with resulting disc swelling and subsequent pallor. It is not associated with vasculitis such as giant cell arteritis (GCA). It is associated with cardiovascular risk factors, especially hypertension.
Occipital lobe lesions	The occipital lobes are one of four main lobes of the cerebral cortex. Lesions in this area can affect visual perception, colour recognition, reading and reading comprehension, as well as depth and the movement of objects. If severe, can cause cortical blindness.
Oculocardiac reflex	A potentially fatal reflex that occurs due to stimulation of the trigeminal nerve. The resultant massive parasympathetic outflow mediated by the vagus nerve can cause bradycardia, hypotension and life-threatening arrhythmias. Entrapment of extraocular muscles by periorbital fractures can cause oculocardiac reflex.
Open globe injury	A full thickness injury to the cornea, sclera or both.
Ophthalmia neonatorum	Neonatal conjunctivitis contracted by newborns during delivery through an infected birth canal.
Ophthalmoplegia	Weakness or paralysis of one of the extraocular muscles that control eye movement and keep the eye in place.
Optic nerve dysfunction	Optic nerve function can be tested by combining examination of the various modalities: visual acuity, pupil function, peripheral fields, colour vision and colour saturation.
Optic neuritis	A demyelinating inflammation of the optic nerve.
Orbital cellulitis	Inflammation of eye tissues behind the orbital septum. It most commonly refers to an acute spread of infection into the eye socket from either the adjacent sinuses or through the blood.
Palpebral fissure	Space between the upper and lower eyelid edges.
Penetrating eye injury	When an object penetrates through the globe with no exit wound.
Periorbital cellulitis	Inflammation and infection of the eyelid and portions of skin around the eye, anterior to the orbital septum. Also known as preseptal cellulitis.
Photopsia	Perceived flashes of light. Associated with posterior vitreous detachment, migraine with aura without headache and retinal break or detachment.

Term	Definition
Pingueculum	A yellowish patch or bump on the conjunctiva, near the cornea. This is a fatty degeneration of the conjunctiva overlying the inner or (less commonly) outer part of the white of the eye. This is a benign condition, usually requiring no treatment. Artificial tears may help to relieve discomfort.
Posterior synechiae	Pathological condition: adhesion of the iris to the cornea/lens.
Posterior vitreous detachment (PVD)	A condition of the eye in which the vitreous membrane separates from the retina. It refers to the separation of the posterior hyaloid membrane from the retina anywhere posterior to the vitreous base.
Presbyopia	Loss of near vision caused by the loss of elasticity of the lens of the eye, occurring typically in middle and old age.
Preseptal cellulitis	Inflammation and infection of the eyelid and portions of skin around the eye, anterior to the orbital septum. Also known as periorbital cellulitis.
Primary gaze	Gaze position determines the effect of extraocular muscle contractions on the rotation of the eye. Primary gaze is when the eyes look straight ahead.
Prolapse	Pathologic condition: slip/falling out of place of a part, e.g. iris may fall through a wound.
Proptosis	Protrusion of the eyeball. Also known as exophthalmos and is usually used when describing proptosis due to Graves' disease.
Pterygium	A fibrovascular overgrowth of the conjunctiva onto the cornea.
Ptosis	Drooping of the upper eyelid, indicative of third nerve palsy, Horner syndrome, injury or swelling of the eyelid.
Ptosis measurement	Lid crease height, margin reflex distance (MRD) and levator function measurements are needed. Ensure the patient's head in a normal position with eyebrows relaxed.
Red reflex	The red reflection seen through the pupil from the retina. This is similar to 'red eye' in flash photography. The reflex is missing if there is an opacity at the cornea, anterior chamber, lens and vitreous or if the retina is detached.
Reduced vision/ decrease in vision acuity	A decreased capacity of vision that is not corrected by glasses.
Relative afferent pupillary defect (RAPD)	A pattern of pupil abnormality which is tested by the 'swinging torch test'. Also known as Marcus Gunn pupil. Abnormal pupillary response in which the pupil initially dilates in response to bright light after bright light has been shone in the contralateral (normal) eye.

Term	Definition
Retinal tear/detachment (RD)	A disorder of the eye in which the retina peels away from its underlying layer of support tissue.
Retrobulbar haemorrhage	A rare, rapidly progressive, sight-threatening emergency that results in an accumulation of blood in the retrobulbar space. It can occur due to orbital trauma, complications of eyelid or orbital surgery or any process that can affect the blood supply to the eye. Immediate referral to an ophthalmologist is needed.
Retropulsion	A push back of the eye. Used in eye examination to detect the level of resistance and orbit mobility.
Scleritis	Inflammation of the sclera.
Scotoma	Blind spot in an otherwise normal vision field.
Seidel test	A test used to reveal ocular leaks from the cornea, sclera or conjunctiva following an injury.
Seventh (7th) cranial nerve palsy	Can cause paralysis of facial muscles on that side and may result in the inability to close the eye (lagophthalmos). This leads to exposure of the corneal surface, which can rapidly cause irreversible corneal damage and blindness. Seek immediate referral to an ophthalmologist.
Sixth (6th) cranial nerve palsy	Causes the inability to abduct the eye. The patient will classically describe horizontal binocular diplopia that is worse on looking to the affected side, and either less marked (or resolved) on looking in the opposite direction or at a near target. Causes that must be excluded include giant cell arteritis (GCA), compression by a tumour and trauma. Bilateral sixth nerve palsy can occur if there is elevated intracranial pressure.
Stroke	A medical emergency when blood flow to the brain is blocked. Seek neurological referral.
Stye	An infection of an oil gland in the eyelid. Also known as hordeolum.
Subconjunctival haemorrhage	Bleeding underneath the conjunctiva.
Subtarsal foreign body	Usually in the upper eyelid. Symptoms include a foreign body sensation, watering and pain.
Superficial punctate epithelial defect	Damage of the epithelium of the cornea in a pinpoint pattern under a slit lamp. Symptoms are nonspecific, including red eye, tearing, foreign body sensation, photophobia and burning. The eye may appear red with a visible foreign body or linear corneal abrasion.

Term	Definition
Symblepharon	Pathologic condition: adhesion of the eyelid conjunctiva to the conjunctiva of the globe.
Tarsal conjunctival	The part of the conjunctiva that lines the inside surface of the eyelid.
Temporal arteritis	See giant cell arteritis (GCA).
Third (3rd) cranial nerve palsy	Classically causes upper lid ptosis, anisocoria (pupil larger on affected side), downwards and lateral deviation of the affected eye and an inability to adduct or elevate the eye. Lesser degrees of palsy can result in a minor ptosis or only partial movement deficits. Causes that must be excluded are an aneurysm of the posterior communicating artery compressing the third cranial nerve, another intracranial mass or pathology in the cavernous sinus, giant cell arteritis (GCA) and trauma.
Thyroid eye disease (TED)	An autoimmune disease that causes inflammation of the eye muscles and fatty tissue behind the eyes. This can cause the eyes to be pushed forward so the eyes 'bulge'. Associated with Graves' disease.
Transient visual obscuration	Temporary or momentary loss of vision in one or both eyes. May be a symptom of a number of conditions depending on its clinical features.
Trichiasis	A condition (such as entropion) resulting in the eyelashes rubbing against the cornea causing discomfort and the potential for ulceration.
Ulceration	Pathologic condition: loss of substance in skin/mucous tissue due to gradual necrosis of the tissue.
Uvea	Term used to describe the 'middle' layer of the eye's internal structure, between the retina and the sclera. It comprises the choroid, ciliary body and iris. Visible uveal tissue following trauma indicates that the globe is ruptured.
Uveal contents	The vascular middle layer of the eye constituting the iris, ciliary body and the choroid.
Uveitis	Inflammation of the middle layer of tissue of the uvea (eye wall). Symptoms include eye redness, pain and blurred vision. Can be unilateral or bilateral.
Valsalva retinopathy	Valsalva retinopathy is a preretinal haemorrhage caused by a sudden increase in intrathoracic or intra-abdominal pressure. Seek an urgent referral to an ophthalmologist.
Vitreous haemorrhage	The extravasation or leakage of blood into the areas in and around the vitreous humour of the eye.